

## *The effects of a modified protraction headgear on maxilla*

Toros Alcan, DDS, PhD,<sup>a</sup> Ahmet Keleş, DDS, DMSc,<sup>a</sup> and Nejat Erverdi, DDS, PhD<sup>b</sup>

*Istanbul, Turkey*

Protraction headgears are commonly used in the treatment of Class III malocclusion characterized by maxillary retrognathism. The upward and forward rotation of the maxilla during protraction is a major unwanted side effect. The aim of this study was to eliminate the upward and forward rotation of maxilla while protracting. Seventeen patients with Class III malocclusion as a result of maxillary retrognathism were treated for 3 months; their average age was 12.81 years. A full coverage acrylic cap splint-type rapid maxillary expansion appliance was cemented and activated twice a day for 5 days. After sutural separation, a maxillary modified protraction headgear was worn and 750 g of force was applied. Wilcoxon signed rank test was carried out to evaluate 42 parameters measured on cephalometric radiographs. The maxilla was displaced anteriorly by downward and backward rotation. The mandible was displaced downward and backward due to anterior elongation of the maxilla. Extrusion and lingual tipping of the upper incisors and intrusion of upper molars and downward and backward rotation of functional occlusal plane were observed. The aim of our study was achieved, which was to avoid upward and forward rotation while protracting the maxilla. In conclusion, maxillary modified protraction headgear (MMPH) can be used effectively in Class III patients with retrognathic maxilla and anterior open bite tendency. (*Am J Orthod Dentofacial Orthop* 2000;117:27-38)

**C**lass III skeletal anomaly is one of the most difficult malocclusions to correct in orthodontics. Class III skeletal malocclusion may result from: (1) maxillary retrognathism, (2) mandibular prognathism, or (3) combined maxillary retrognathism and mandibular prognathism. In order to treat Class III cases, the position of the responsible jaw that causes the malocclusion should be corrected. Ellis and McNamara<sup>1</sup> found that 65% to 67% of all Class III malocclusions were characterized by maxillary retrognathism. Numerous studies have been conducted to find new ways to correct Class III skeletal malocclusion. Some investigators<sup>2-11</sup> used chincups to correct these Class III skeletal patterns. However, mandibular treatment alone is not sufficient to correct retrognathic maxillary position. Protraction of nasomaxillary complex on skeletal Class III cases has been accomplished in some experimental and clinical studies.<sup>12-16</sup> In the late 1960s, the Delaire<sup>17</sup> mask was popularized to protract the maxilla. In this appliance design, extraoral anchorage regions were the chin and forehead. However, upward and forward rotation of maxilla and downward and backward rotation of mandible were also observed. In 1983,

Petit<sup>18</sup> modified the Delaire mask. In essence, his facial mask consisted of a forehead pad and a chin pad that were connected with a heavy steel rod. Intraorally, a bonded rapid palatal expansion appliance was used. Forward traction of the maxilla was accomplished by rubber bands. The treatment results produced by this appliance were the anterior movement of the maxilla and downward and backward rotation of the mandible. Kambara,<sup>19</sup> in animal studies, demonstrated that maxillary anterior displacement was accompanied by upward and forward rotation of the maxilla. Nanda<sup>20</sup> reported that the midfacial complex of *Macaca mulatta* monkeys could be displaced anteriorly by sutural modification, and his histologic findings supported those of Kambara's.<sup>19</sup> Nanda<sup>21</sup> introduced a modified protraction headgear face bow that aimed to control the point of force application and direction of the force. The forehead and the chin were used as areas of support. According to Nanda,<sup>21</sup> the nature of movement of the maxillary complex was related to the direction of the force and the point of force application. He claimed that applying the force to the maxilla at the occlusal level would cause upward and forward rotation of the maxilla. With this new face bow design the point of force application was moved above the occlusal plane. Nanda's results showed that maxilla translated forward; however, downward and backward rotation of mandible and maxillary molar extrusion were unavoidable. According to Tanne et al<sup>22</sup> and Hirato,<sup>23</sup> the location of the center of resistance of maxilla is between the first and the second upper premolar root apexes.

From the Department of Orthodontics, Faculty of Dentistry, University of Marmara, Istanbul, Turkey.

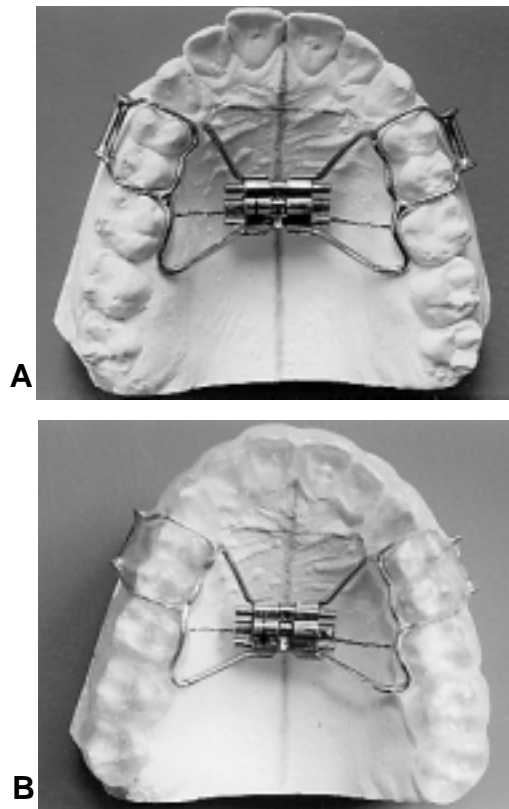
<sup>a</sup>Assistant Professor.

<sup>b</sup>Professor.

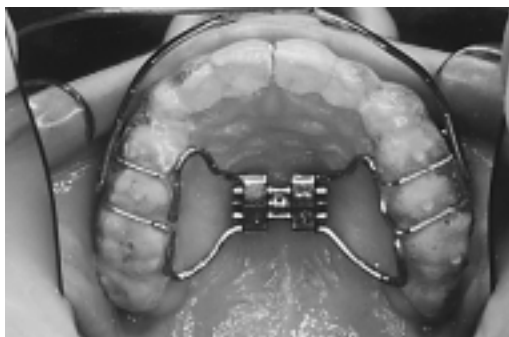
Reprint requests to: Ahmet Keleş, Halaskarquzi cad. Halas, Apt. 275/4 Osmanbey 80220, Istanbul, Turkey; e-mail, aokeles@hotmail.com

Copyright © 2000 by the American Association of Orthodontists.

0889-5406/2000/\$12.00 + 0 8/1/97816

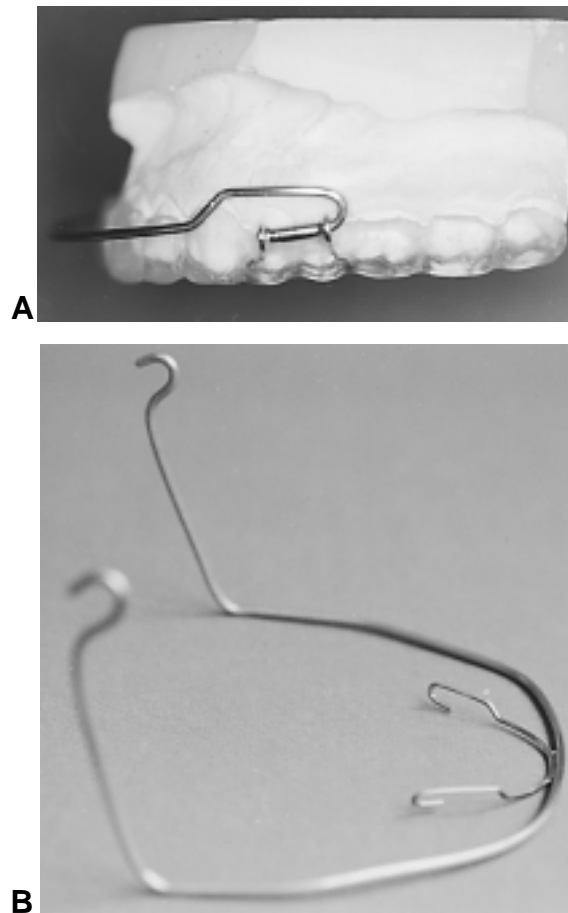


**Fig 1.** **A**, Tubes were soldered to the RME screw at the premolar buccal region; **B**, full coverage acrylic cap splint type RME appliance.



**Fig 2.** Acrylic cap splint in the mouth.

Ichikawa et al<sup>24</sup> and Kawagoe et al<sup>25</sup> reported in their previous studies that conventional maxillary protraction headgears cause extrusion and anterior rotation of the anchor teeth, and upward and forward rotation of the maxilla. Later Hata et al<sup>26</sup> and Itoh et al<sup>27</sup> examined the biomechanical effects of maxillary protraction on the craniofacial complex on dry human skulls. Their results indicated that protraction forces at the level of the maxillary arch produced an upward



**Fig 3.** **A**, Intraoral component of face bow (left lateral view); **B**, face bow of extraoral appliance (ready to apply).

and forward rotation and an anterior movement of the maxilla. They showed that protraction forces applied 10 mm above the Frankfort horizontal plane produced a downward and backward rotation of the maxilla with an anterior movement of nasion. In addition, protraction forces that applied 5 mm above the palatal plane produced a combination of parallel forward movement with downward and backward rotation of the maxilla. Constriction of the anterior part of the palate occurred in all these cases.

Previous studies have shown both the effects and side effects of the application of protraction forces on the maxillary complex. In order to achieve optimal treatment results, the malocclusion should be properly diagnosed. Until recently most of the current appliances could not prevent the upward and forward rotation of the maxilla and downward and backward rotation of the mandible. As shown by the research cited above, the most important things to be considered in maxillary protraction are the point of the force applica-

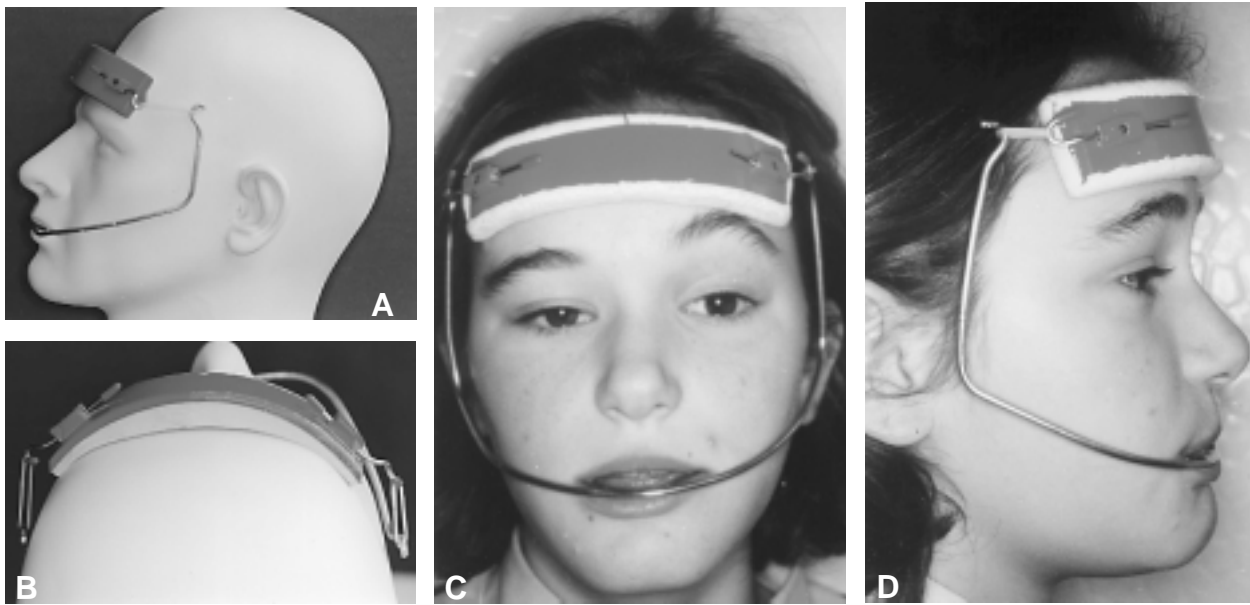


Fig 4. Heavy (750 g) protraction elastics of MMPH.

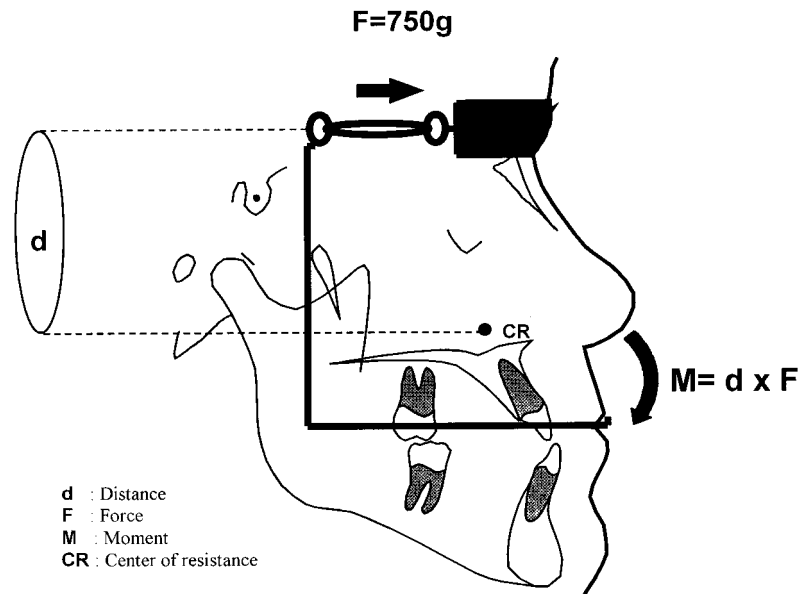
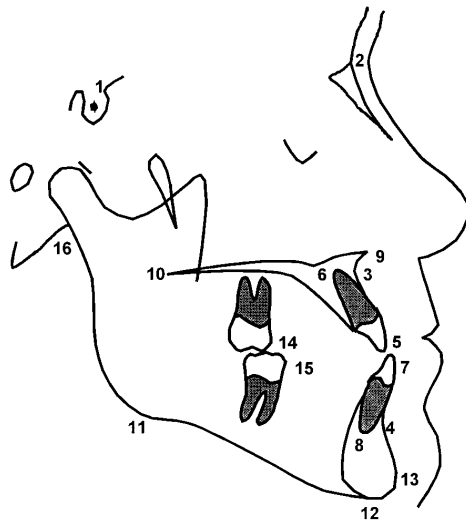


Fig 5. Force and moment system of MMPH.

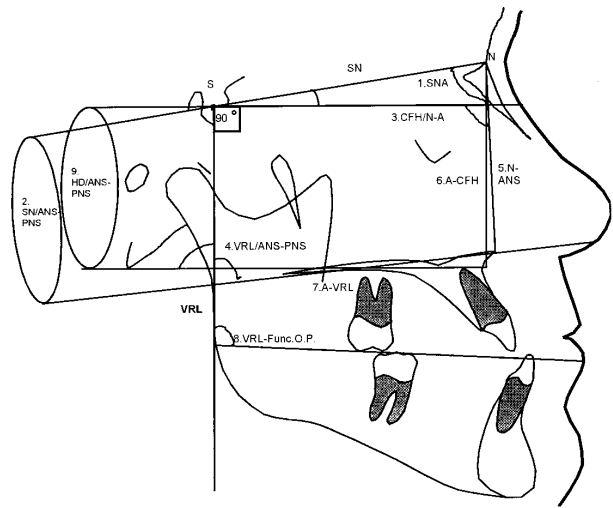
tion and the direction of the force. In theory, correction of a retrognathic maxilla should not affect the orthognathic mandible. As the mandible is attached to the head with temporomandibular joint (TMJ), it rotates around the condylar axis when opening and closing the mouth. It is impossible to really stabilize the force system in reverse pull headgear, which takes anchorage from the chin, because the movement of the mandible does not allow us to apply a consistent force. Another very important aspect that needs to be considered is the

uncertain effect of maxillary orthopedic forces on the TMJ and on mandibular growth. In growing children, force application to the chin by reverse-pull headgear causes downward and backward rotation of mandible. Grummons<sup>28</sup> claimed that reverse headgears might have harmful effects on the TMJ because they take support from the mandible. In 1997, Conte et al<sup>29</sup> developed a new appliance called "Maxillary Protractor," which took anchorage from forehead, temporal, and occipital regions. These investigators claimed that if

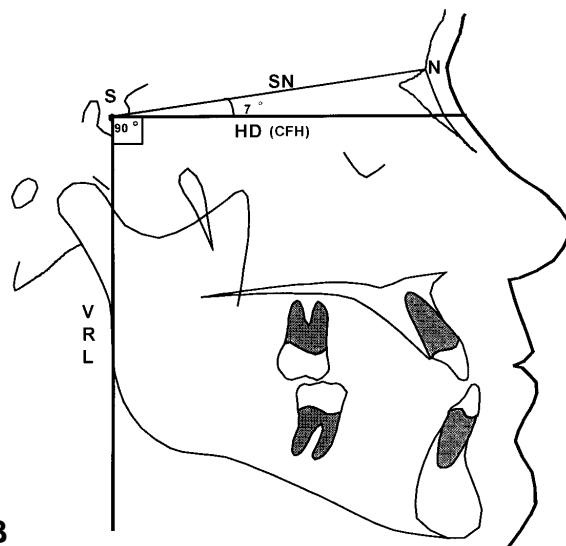


1	S	Sella	9	ANS	Anterior nasal spine
2	N	Nasion	10	PNS	Posterior nasal spine
3	A	A point	11	Go	Gonion
4	B	B point	12	Me	Menton
5	Isi	Upper incisor incisal edge	13	Pg	Pogonion
6	Isa	Upper incisor apical edge	14	Ms	Upper first molar mesial convexity
7	lii	Lower incisor incisal edge	15	Mi	Lower first molar mesial convexity
8	lia	Lower incisor apical edge	16	Ar	Articulare

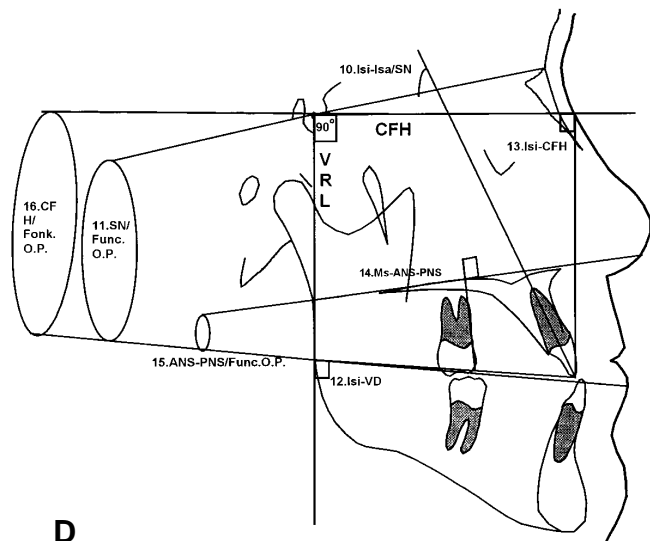
A



C



B



D

**Fig 6.** A, Cephalometric landmark points on the cephalometric films; B, reference lines on the cephalometric films; C, maxillary skeletal cephalometric variables; D, maxillary dental cephalometric variables.

the force is not applied to mandible, any potential TMJ dysfunction is prevented.

To eliminate the potential adverse effects of the previous versions of reverse-pull headgears, we have developed a modified protraction headgear design. Our aim in planning this headgear design was to protract the maxilla without upward and forward rotation in skeletal Class III patients, which were classified as having a ret-

rognathic maxilla and an orthognathic mandible. In our appliance design, the point of force application is positioned above the center of resistance of maxilla. We have not used the mandible for anchorage because of the potential deleterious effects of distal force on the TMJ. A full coverage acrylic cap splint type-rapid maxillary expansion (RME) appliance was used intraorally to release the maxilla prior to the protraction.

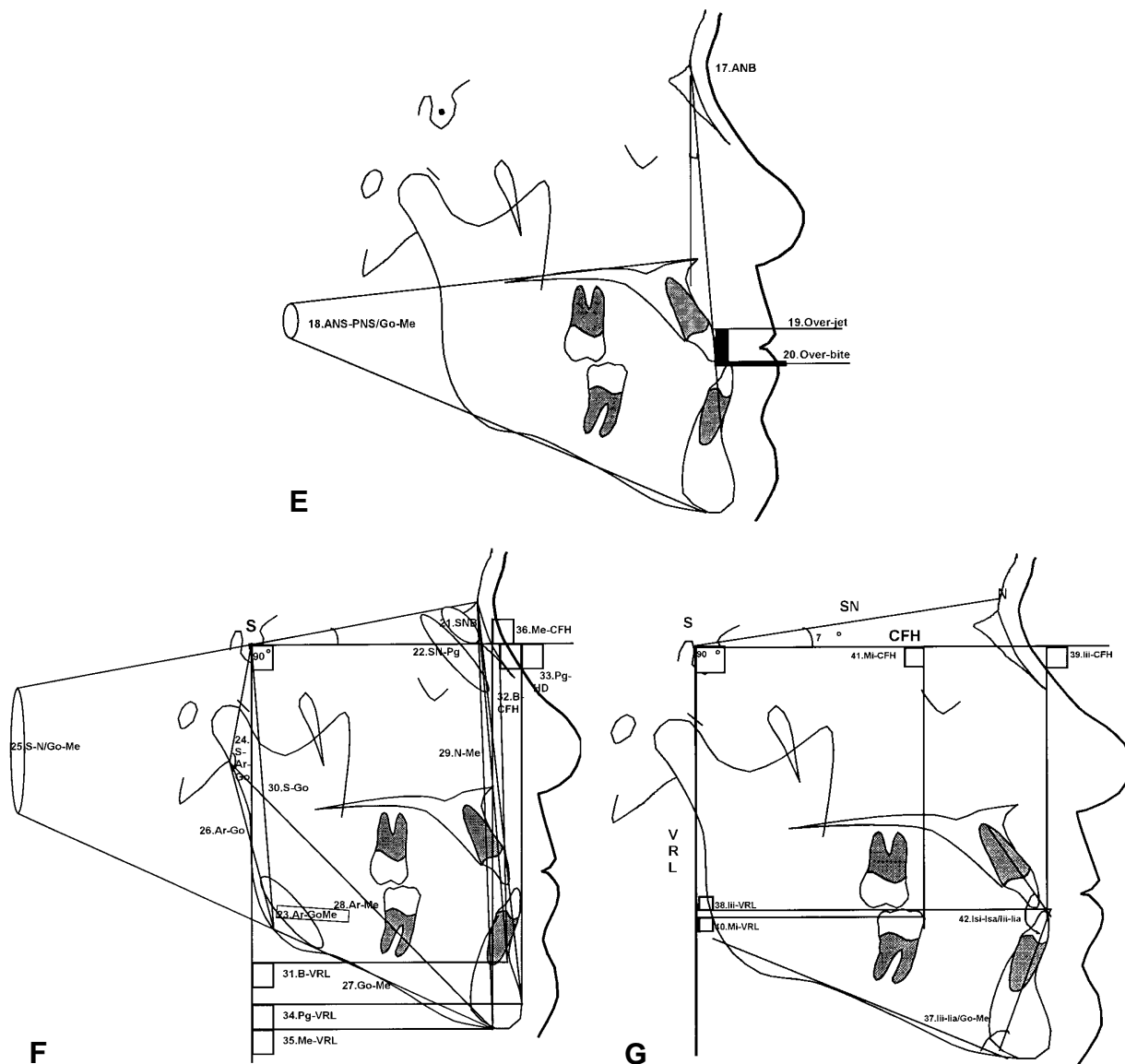


Fig 6. cont'd. E, intermaxillary variables; F, mandibular skeletal cephalometric variables; G, mandibular dental cephalometric variables.

## MATERIAL AND METHODS

### Case Selection

In our study, we selected 17 patients (12 female and 5 male) at the University of Marmara, Faculty of Dentistry, İstanbul. The age of the male patients ranged from 11.41 to 14.25 years with an average age of 13.14 years. The age of the female patients ranged from 10.56 to 13.50 years with an average of 12.49 years. Mean age for the study group was 12.81 years. As for case selection criteria, the patients were required to show maxillary retrognathism with a normal or high angle growth pattern, Class III molar relationship with an overjet less

than 0 mm (ANB angle  $< 1^\circ$ , SNA angle  $< 80^\circ$  for girls, and SNA angle  $< 80^\circ$  for boys, SN-GoMe angle  $> 32^\circ$ ).

### Intraoral Appliance

A full coverage acrylic cap splint type RME appliance that covered all the maxillary dentition was constructed. The thickness of the acrylic was about 3 mm. On both buccal sides of the acrylic splint, tubes (8 mm in length and 1.65 mm in diameter) were placed in the premolar region. Retention wires that extended to the expansion screw were soldered to the tubes. These tubes were used for the engagement of the face bow's inner arch.

**Table I.** Skeletal changes related to maxilla

	<i>Before protraction</i>		<i>After protraction</i>		<i>Median</i>		<i>Wilcoxon</i>	<i>Significance</i>
	<i>X</i>	<i>SD</i>	<i>X</i>	<i>SD</i>	<i>Before protraction</i>	<i>After protraction</i>		
1 SNA	77.32	2.24	79.61	2.53	77	80	0.0004	***
2 SN\ANS-PNS	9.88	1.70	11.55	1.67	10.5	11.5	0.0016	**
3 CF-NA	84.05	2.31	87.02	3.56	84	88	0.0003	**
4 VRL-ANS-PNS	91.5	5.64	93.17	4.12	93	93	0.0084	**
5 N-ANS	53.29	3.09	55.17	3.50	52.5	55	0.0007	***
6 A-CFH	53.17	2.76	56.05	4.13	53	55	0.0007	***
7 A-VRL	61.44	3.50	63.58	4.19	62	64	0.0004	***
8 VRL-FuncOP	104.85	3.20	112.9	6.07	105.5	112	0.0003	***
9 CFH\ANS-PNS	4.44	2.09	5.70	2.20	5	6.5	0.0029	**

\**P*<.05; \*\**P*<.01; \*\*\**P*<.001.**Table II.** Maxillary dental changes

	<i>Before protraction</i>		<i>After protraction</i>		<i>Median</i>		<i>Wilcoxon</i>	<i>Significance</i>
	<i>X</i>	<i>SD</i>	<i>X</i>	<i>SD</i>	<i>Before protraction</i>	<i>After protraction</i>		
10 Isi-Isa\SN	104.41	6.24	99.91	10.03	105	102	0.0052	**
11 SN\FuncOP	20.70	3.19	28.78	6.48	20	27.5	0.0003	***
12 Isi-VRL	64.08	5.36	63.23	6.67	64	64	0.3003	
13 Isi-CFH	74.38	4.05	77.29	5.40	74	77.5	0.0018	**
14 Ms.\ANS-PNS	20.08	2	18	1.59	20	18	0.0003	***
15 ANS-PNS\FOP	12.97	5.30	18.44	6.66	11.5	18	0.0004	***
16 CFH\FuncOP	13.91	2.65	22.88	7.49	13.5	21	0.0003	***

\**P*<.05; \*\**P*<.01; \*\*\**P*<.001.**Table III.** Intermaxillary changes

	<i>Before protraction</i>		<i>After protraction</i>		<i>Median</i>		<i>Wilcoxon</i>	<i>Significance</i>
	<i>X</i>	<i>SD</i>	<i>X</i>	<i>SD</i>	<i>Before protraction</i>	<i>After protraction</i>		
17 ANB	-1.5	1.67	1.88	1.02	-1	1.5	0.0003	***
18 ANS-PNS\GoMe	26.08	3.67	27.44	4.52	24	26	0.0303	*
19 Overjet	-1	1.33	1.52	1.19	-1	1	0.0003	***
20 Overbite	0.32	0.76	1.14	0.87	0	1	0.0362	*

\**P*<.05; \*\**P*<.01; \*\*\**P*<.001.

The design of the intraoral appliance is illustrated in Fig 1. After cementation of the RME appliance with fluoride-releasing glass ionomer cement (3M-Unitek REF 712-051-2724), the palatal screw was activated twice a day for 5 days (total of 2 mm expansion). At the end of the fifth day, the protraction headgear was applied (Fig 2).

### Extraoral Appliance

The extraoral appliance consisted of a face bow and forehead pad. The face bow had intraoral and extraoral components and was custom-made individually for each patient. The intraoral bow (1.55 mm in diameter) was inserted from the distal openings of the

tubes (Fig 3A). It was soldered to the extraoral face bow, 10 mm in front of the incisor region of the cap splint. The extraoral face bow (3 mm in diameter) was extended backward to the ear then turned upward, ending at the level of the hooks on the forehead pad (Fig 3B). The distance between the wire hooks on the forehead pad and the hooks of the extraoral face bow was adjusted to 3 cm. In this extraoral appliance design, only the forehead was used as the anchorage unit. Delaire mask's forehead piece was used and modified. On both sides of the pad, adjustable wire hooks (1.2 mm in diameter) were placed that allowed us to maintain the distance from the forehead pad

**Table IV.** Skeletal changes related to mandible

	Before protraction		After protraction		Median		Wilcoxon	Significance
	X	SD	X	SD	Before protraction	After protraction		
21 SNB	78.64	2.69	77.47	3.47	79	77.5	0.0064	**
22 SN-Pn	80.05	2.89	78.76	3.52	81	79	0.0026	**
23 Ar-Go-Me	126.91	4.98	127.6	4.90	127	129	0.0329	*
24 S-Ar-Go	145	5.75	146.1	6.02	146	145	0.0207	*
25 SN\Go-Me	36.38	3.11	38.43	4.48	35	37.5	0.0064	**
26 Ar-Go	46.17	5.68	45.9	4.38	44	44.5	0.1095	
27 GoMe	70	3.64	69.91	3.58	69	70	1	
28 Ar-Me	103.47	4.27	103.9	4.06	103.5	104	0.0609	
29 Na-Me	118.44	4.80	120.9	5.85	119	121	0.0004	***
30 S-Go	74.85	4.94	75.7	4.59	74	75	0.0022	**
31 B-VRL	57.91	6.08	56.61	7.13	56	56	0.0202	*
32 B-CFH	92.79	4.69	95.11	6.86	92.5	94	0.0007	***
33 Pg-CFH	103.79	3.69	106.1	5.68	104	105	0.0006	***
34 Pg-VRL	59	7.81	57.17	8.45	56	55	0.0011	**
35 Me-VRL	51.5	7.12	48.12	8.41	51	50	0.0041	**
36 Me-CFH	108.76	4.65	111.4	5.47	109	111	0.0005	***

\* $P < .05$ ; \*\* $P < .01$ ; \*\*\* $P < .001$ .

**Table V.** Mandibular dental changes

	Before protraction		After protraction		Median		Wilcoxon	Significance
	X	SD	X	SD	Before protraction	After protraction		
37 Iii-Iia\Go Me	88.02	3.59	85.17	3.59	88	86	0.0070	***
38 Iii\VRL.	64.38	5.53	61.79	6.38	65	63	0.0005	**
39 Iii\CFH	73.47	3.70	76.08	4.86	74	76	0.0003	**
40 Mi-VRL	40.35	4.04	38.94	5.11	40	39	0.0039	**
41 Mi-CFH	70.47	3.04	72	4.5	70	72	0.0080	**
42 Isi-Isa/Iii-Iia	131.5	4.82	137.64	8.71	132	136	0.0097	**

\* $P < .05$ ; \*\* $P < .01$ ; \*\*\* $P < .001$ .

hooks to the face bow hooks. For patient comfort and for better adaptation to the forehead, the inner surface of the pad was covered with silicone and soft-liner material. Heavy elastics (2H [3/16 inch] 14 oz, Ormco Corp) were attached between the hooks of the face bow and the hooks on the forehead pad. A total of 750 g of protrusive force was applied, and the force was oriented parallel to the Frankfort horizontal plane (Fig 4). The extraoral appliance was worn for at least 17 hours per day for 3 months (Fig 4). At the end of the third month, the appliance was removed and records were taken (cephalometric x-rays and intraoral and extraoral pictures). The force-moment systems of the extraoral appliance are demonstrated in Fig 5.

**Cephalometric Method**

Pretreatment and posttreatment lateral cephalograms were carefully traced for each patient on 8 × 10 inch acetate paper. Each pair of radiographs of a patient was

traced at the same sitting to minimize tracing errors. Sixteen cephalometric landmark points (Fig 6A), 3 reference lines (Fig 6B), and 42 cephalometric variables (27 skeletal, 15 dental) (Fig 6C, D, E, F, G) were used in this study. The positional changes of the cephalometric landmarks between the two tracings were measured by a Cartesian coordinate system. A horizontal reference line (CFH) constructed by reducing 7° from the sella-nasion line was used as the X axis. Because of problems with reproduction of the conventional Frankfort horizontal (FH) plane, a constructed FH plane is used. A vertical line (VRL) passing through sella and perpendicular to the X axis served as the Y axis. All measurements were taken to the nearest 0.5 mm.

**Statistical Method**

Skeletal and dental changes related to maxilla and mandible were analyzed with Wilcoxon signed rank test. NCSS (Number Cruncher Statistical System) computer package was used on an IBM PC. The mean,

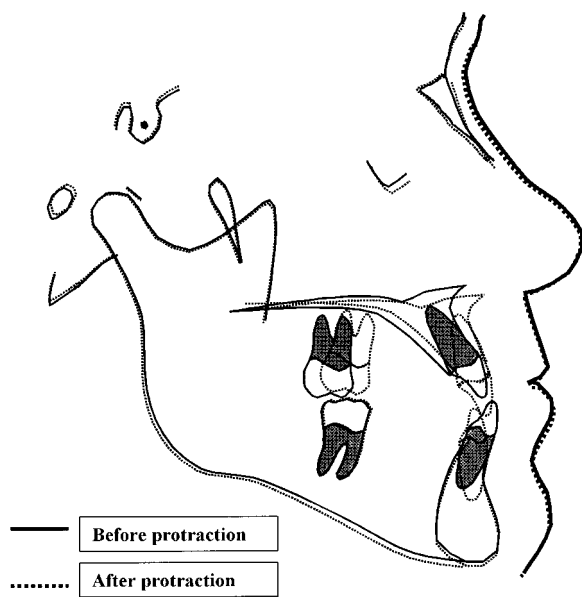


Fig 7. Composite superimposition.

median, and standard deviations were calculated for each measurement. The normal distribution of the values were not assumed in this study. But means and standard deviation were used for better presentation technique and to show all aspects of the variables.

## RESULTS

Cephalometric analysis revealed that at the end of the third month the maxilla advanced anteriorly. The distance between the VRL and point A increased by 2.14 mm, whereas the SNA angle increased by 2.29°. The maxilla rotated in a downward and backward direction, as indicated by the 1.67° increase in SN to palatal plane (ANS-PNS) angle (Table I). Dentally, maxillary incisors were extruded, and the angle between functional occlusal plane (FOPln) and SN increased by 8.08° (Table II). There was 2.52 mm increase in overjet and 0.82 mm increase in overbite (Table III). The mandible rotated slightly in a downward and backward direction, as shown by the 1.87° increase in mandibular plane (Go-Me) to SN angle. Anterior total face height increased by 2.05 mm (Table IV). Maxillary incisors were extruded and tipped palatally; mandibular incisors were tipped lingually, thus increasing the interincisal angle (Table V). Maxillary molars were intruded by 2.08 mm. Clinically, patients wore the appliance without any discomfort. All the cephalometric changes related to maxilla, mandible, and intermaxillary changes as well as maxil-

lary and mandibular dental changes are presented in Table I-V and in Fig 7.

## DISCUSSION

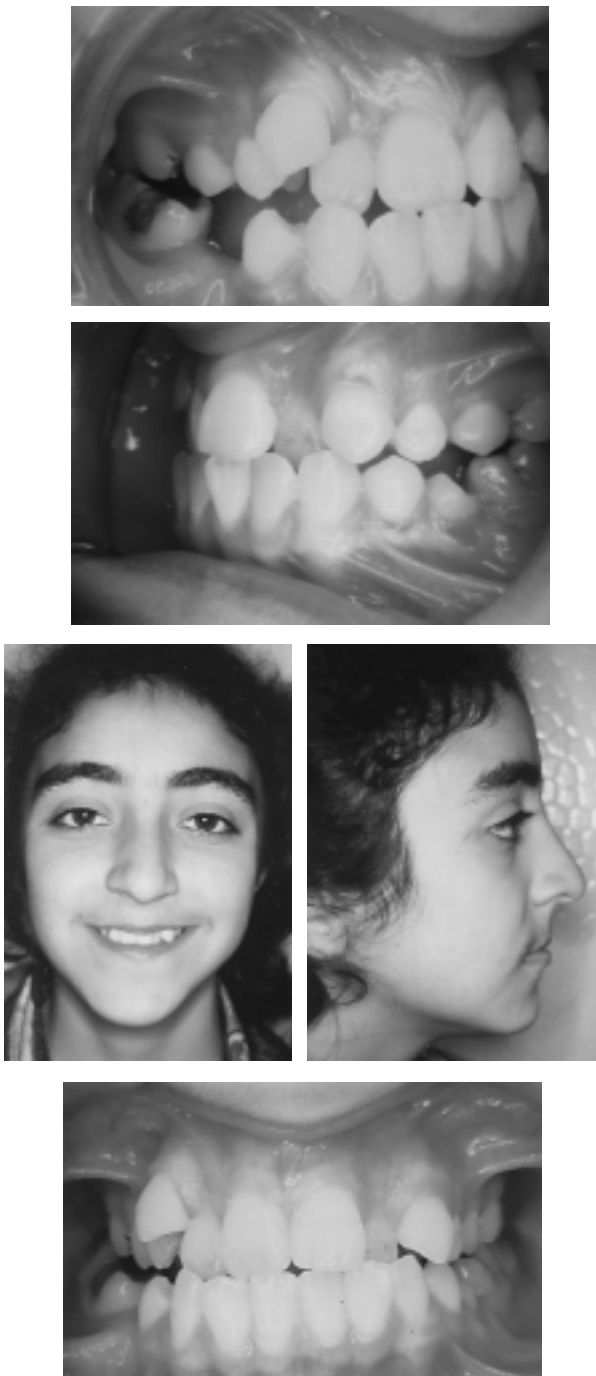As mentioned earlier, our purpose in developing MMPH was to protract the maxilla without upward and forward rotation in Class III patients with retrognathic maxilla and orthognathic mandible. The average age of the 17 patients that were selected for study group was 12.81 years. Mermigos et al<sup>30</sup> claimed that early treatment of Class III patients with protraction headgear would stimulate sutural activity. However, in an article from 1997, Merwin et al<sup>31</sup> stated that there was no difference between the age groups of 5 to 8 and 8 to 12 years from the point of protraction of the maxilla.

In our study, we expanded the maxilla for 5 days (2 turns/day) before protraction. On the fifth day, sutural opening was observed on the occlusal radiographs. After the fifth day, activation of the screw was discontinued because posterior anatomic structures would displace the maxilla anteriorly and would not allow us to examine the effect of protraction headgear only. The total amount of activation of the screw was 2 mm. Proffit and Fields<sup>32</sup> claimed that before protraction of the maxilla, transversal expansion had to be done in order to enhance protraction. There are other studies<sup>21,33-43</sup> in the literature that support the concept that RME procedures release maxilla's sutures with the surrounding bones and enhance the protraction procedure.

In the present study, a full coverage acrylic cap splint type RME appliance was used in order to increase the rigidity of the appliance, to prevent the occlusal interferences, to apply homogeneous force, and to maximize the skeletal effect of the protraction headgear. Previous investigations<sup>38,43-45</sup> showed that the application of cap splint type maxillary expansion appliances would increase the skeletal effect of the protraction headgear. According to Haas,<sup>36</sup> the use of acrylic cap splint type RME appliance would allow homogeneous force distribution during maxillary expansion.

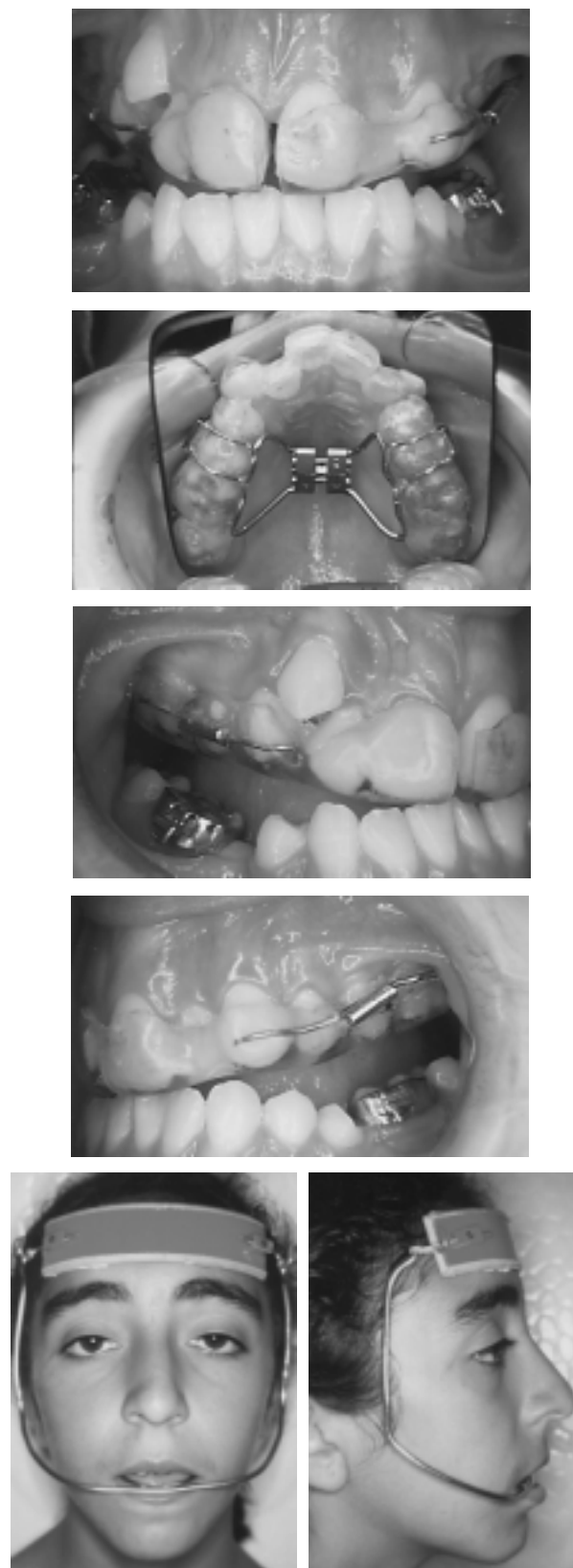
In our appliance design, the force was applied at the forehead pad level, which is above the center of resistance of the maxilla. The direction of the force was forward and parallel to the Frankfort horizontal plane. Previously, different kinds of headgear designs were examined in various studies; however, upward and forward rotation of maxilla appeared unavoidable. Hickham,<sup>46</sup> Mermigos et al,<sup>30</sup> and Wisth et al<sup>47</sup> applied the protraction force at the canine region. Spolyar<sup>42</sup> applied the force at premolar or deciduous molar region in order to minimize the upward and forward rotation. Kambara<sup>19</sup> claimed that in order to maximize



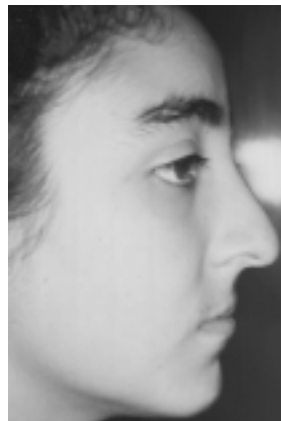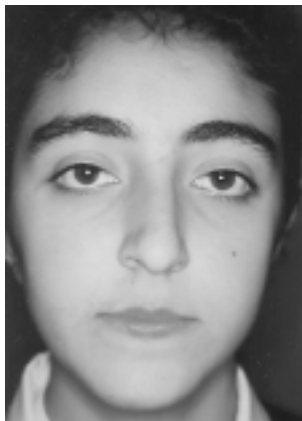
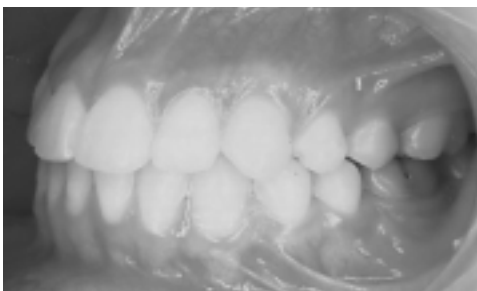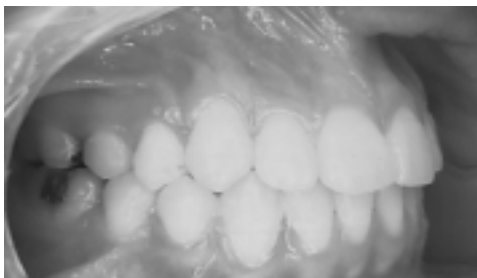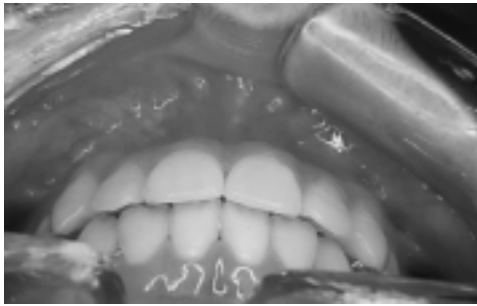
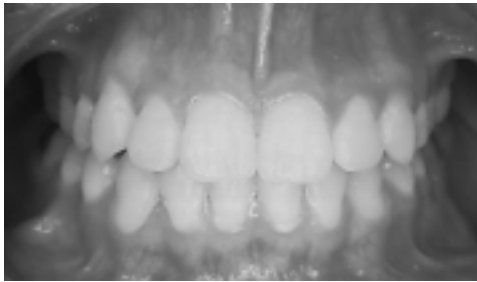


**Fig 8.** Pretreatment facial and intraoral photographs.

protraction and minimize the upward and forward rotation of the maxilla, the point of force application should be moved mesially. Roberts and Subtelny<sup>48</sup> and Verdon<sup>49</sup> moved the point of force application distal to the laterals in order to prevent anterior open bite while protracting the maxilla. However, upward and forward rotation of the maxilla was unavoidable. Itoh et al<sup>27</sup>



**Fig 9.** Protraction completion facial and intraoral photographs.



**Fig 10.** Posttreatment facial and intraoral photographs.

claimed that upward and forward rotation of the maxilla was due to the direction of the force. He recommended applying the force in a downward and forward direction rather than parallel to the horizontal plane. Numerous investigators<sup>27,47-53</sup> examined the effects of force application at an angle of 15° to 30° below the occlusal plane in order to prevent upward and forward rotation of the maxilla. However, their findings also showed that upward and forward rotation of maxilla was unavoidable. In summary, none of these approaches could prevent the upward and forward rotation of the maxilla. According to Tanne et al<sup>22</sup> and Hirato,<sup>23</sup> the center of resistance of the maxilla was located in between the root apices of first and second premolars. Ichikawa et al<sup>24</sup> and Kawagoe,<sup>25</sup> in their studies on dry human skulls, showed that protraction forces, which were at the level of occlusal plane, created upward and forward rotation. Applying the force 5 mm above the palatal plane caused forward movement of maxilla in conjunction with downward and backward rotation, whereas force application 10 mm above the Frankfort horizontal plane created downward and backward rotation of maxilla along with forward movement of nasion. Lee et al<sup>52</sup> developed an "antenna-type modified protraction headgear" that moved the point of force application above the center of resistance of the maxilla. They concluded that for anterior translation of the maxilla, protraction force should be 500 g, the point of force application should be 15 mm above the occlusal level, and the force should be applied at an angle of 20° below the occlusal plane. Stagers et al<sup>54</sup> and Nanda<sup>21</sup> designed a facebow, with which the point of force application would be carried above the occlusal plane in order to prevent upward and forward rotation of the maxilla. However, extrusion of the maxillary molars and downward and backward rotation of the mandible were observed in most of their treated cases.

In our study, 750 g of protrusive force was applied for 17 to 20 hours per day. The duration of the treatment was 3 months. Haas<sup>36</sup> claimed that in order to obtain orthopedic force, the amount of force had to exceed 1 pound (454 g). Nanda,<sup>20</sup> Cozzani,<sup>38</sup> Hickham,<sup>46</sup> and Roberts and Subtelny<sup>48</sup> applied forces that varied between 500 and 1000 g.

Some investigators<sup>48,49,55</sup> have decreased appliance wear to 10 to 14 hours per day; however, they extended the total treatment duration up to 1 year. Nanda<sup>21</sup> claimed that 24 hour appliance wear would achieve more orthopedic effect than 16 hour appliance wear. McNamara<sup>56</sup> also suggested that full day appliance wear would increase the amount of skeletal protraction.

To examine the skeletal changes that were related to maxilla, 6 angular and 3 linear parameters were analyzed in the present study (Table I). The sagittal para-

meters related to maxilla show that there was  $2.29^\circ$  increase in SNA angle ( $P < .001$ ). The angle between the horizontal plane and NA increased by  $2.97^\circ$  ( $P < .01$ ). These results suggest that this appliance was effective in protracting the maxilla anteriorly. Previous investigators found similar results with different kinds of protraction headgear designs. However, if we examine the vertical changes related to the maxilla, the angle between the horizontal plane and ANS-PNS plane increased by  $1.26^\circ$  ( $P < .01$ ). The angle between SN and ANS-PNS plane increased by  $1.67^\circ$  ( $P < .01$ ). The distance from the horizontal plane to point A increased by  $2.88$  mm ( $P < .001$ ). The angle between the horizontal plane and functional occlusal plane increased by  $8.11$  ( $P < .001$ ). These results indicated downward and backward rotation of the maxilla. These findings were contrary to the previous investigations. This may be related to the point of force application of the conventional headgears.

To analyze the dental changes related to maxilla, we used 7 parameters (Table II). The distance between the horizontal plane (H. Pln.) and maxillary incisors increased by  $2.91$  mm ( $P < .01$ ) indicating extrusion of the maxillary incisor. Maxillary incisors were also retroclined as shown by the  $4.5^\circ$  ( $P < .01$ ) decrease in SN to maxillary incisor axis angle. Maxillary molars were intruded as indicated by the  $-2.08$  mm ( $P < .001$ ) decrease in the distance between the maxillary first molars and ANS-PNS plane. The functional occlusal plane was rotated in a downward and backward direction. SN to functional occlusal plane angle increased significantly ( $P < .001$ ). Posterior open bite was observed after the removal of the appliance. All these findings were also at variance with the findings related to previously introduced reverse headgears. These results may be related to the point of force application used in the present study. The adverse effects of conventional headgears were proclination of the upper incisors, extrusion of the molars and opening of the anterior bite.

Skeletal and dental parameters related to the mandible were not mentioned in the present study. As discussed previously, downward and backward rotation of the mandible is related to the downward and backward rotation of the maxillary dentition, and the extrusion of the anterior teeth. The final evaluation of cephalometric changes related to the mandible should be done at the end of fixed orthodontic therapy. In our view, downward and backward rotation of the mandible is reversible and related to the downward and backward rotation of the maxillary dentition, which could be corrected by fixed orthodontic treatment (Fig 8-10).

## CONCLUSION

This newly developed modified headgear MMPH can be used very effectively in Class III patients with a retrognathic maxilla in conjunction with an anterior open bite tendency. The aim of our study to avoid upward and forward rotation during the protraction of the maxilla was achieved. Future studies are needed in order to examine the long-term stability of the skeletal and dental changes related to maxilla and mandible.

## REFERENCES

1. Ellis EE, McNamara JA Jr. Components of adults Class III open-bite malocclusion. *Am J Orthod* 1984;85:277-90.
2. Mitani H, Fukazawa H. Effects of chin force on the timing and amount mandibular growth associated with anterior reversed occlusion (Class III malocclusion) during puberty. *Am J Orthod Dentofacial Orthop* 1986;90:454-63.
3. Graber LW. The alterability of mandibular growth. In: McNamara JA Jr, editor. Determinants of mandibular form and growth. Monograph 5, Craniofacial Growth Series. Ann Arbor Center For Human Growth and Development, University of Michigan 1975; p. 229-41.
4. Sakamoto T, Iwase I, Uka A, Nakamura S. A roentgenocephalometric study of skeletal changes during and after chin cup treatment. *Am J Orthod* 1984;85:341-9.
5. Jansen EK, Bluhner JA. The cephalometric, anatomic, and histologic changes in *Macaca mulatta* after application of continuous-acting retraction force on mandible. *Am J Orthod* 1965;51:825-55.
6. Graber TM. Dentofacial orthopedics. In: Graber TM, editor. Current orthodontic concepts and techniques. Philadelphia: WB Saunders; 1969; p. 919-88.
7. Assano T. The effects of mandibular retractive force on the growing rat mandible. *Am J Orthod Dentofacial Orthop* 1986;90:464-74.
8. Graber LW. Chin cap therapy for mandibular prognathism. *Am J Orthod* 1977;72:23-41.
9. Wendell PD, Nanda R, Sakamoto T, Nakamura S. The effects of chin cup therapy on the mandible: a longitudinal study. *Am J Orthod* 1985;87:265-74.
10. Rittucci R, Nanda R. The effects of chin cup therapy on the growth and development of the cranial base and midface. *Am J Orthod Dentofacial Orthop* 1982;90:475-83.
11. Thilander B. Treatment of angle Class III malocclusion with chin cup. *Trans Eur Orthod Soc* 1963;39:384-98.
12. Oppenheim A. A possibility for physiologic orthodontic movement. *Am J Orthod* 1944;30:345-68.
13. Marx R. Various types of extra-oral anchorage appliances. *Dent Pract* 1961;11:203-6.
14. Nelson FO. A new extra-oral orthodontic appliance. *Int J Orthod* 1968;6:24-7.
15. Sheridan JJ. Oral orthopedics. *J La Dent Assoc* 1968;26:5-8.
16. Dellinger EL. A preliminary study of anterior maxillary displacement. *Am J Orthod* 1973;63:509-16.
17. Delair J. La croissance maxillaire. *Trans Eur Orthod Soc* 1971;81-102.
18. Petit H. Adaptation following accelerated facial mask therapy. In: McNamara JA Jr, Ribbens KA, Howe PR, editors. Clinical alteration of the growing face. Monograph 14, Craniofacial Growth Series. Ann Arbor: Center for Human Growth and Development, University of Michigan 1983;253-89.
19. Kambara T. Dentofacial changes produced by extraoral forward force in the *Macaca Irus*. *Am J Orthod* 1977;71:249-77.
20. Nanda R. Protraction of maxilla in rhesus monkeys by controlled extraoral forces. *Am J Orthod* 1978;74:121-41.
21. Nanda R. Biomechanical and clinical considerations of modified protraction headgear. *Am J Orthod* 1980;78:125-39.
22. Tanne K et al. Three dimensional model of the human craniofacial skeleton: method and preliminary results using finite elements analysis. *J Biomed Eng* 1988;10:246-52.
23. Hirato R. An experimental study of the center of resistance of nasomaxillary complex: two-dimensional analysis on the coronal plane of the dry skull. *J Tokyo Dent Coll* 1984;84:1225-62.
24. Ichikawa K. The effects of orthopedics forces on the craniofacial complex utilizing maxillary protraction. *J Jpn Orthod Soc* 1984;43:326-38.
25. Kawagoe H. Photoelastic effects of maxillary protraction on craniofacial complex. *J Jpn Orthod Soc* 1984;43:337-45.
26. Hata S, Itoh T, Nakagawa M, Kamogashira K, Ichikawa K, Matsumoto M, Chaconas JS. Biomechanical effects of maxillary protraction on the craniofacial complex. *Am J Orthod Dentofacial Orthop* 1987;91:305-11.
27. Itoh T, Chaconas JS, Caputo AA, Matyas J. Photoelastic effects of maxillary protraction on the craniofacial complex. *Am J Orthod* 1985;88:117-24.
28. Grummons D. Orthodontics for the TMJ-TMD patients. Scottsdale: Wright & Co, 1994.
29. Conte A, Carano A, Sciliani G. A new maxillary protractor. *J Clin Orthod*, 1997;31:523-30.
30. Mermigios J, Full CA, Andreasen G. Protraction of the maxillofacial complex. *Am J Orthod Dentofacial Orthop* 1990;98:47-55.

31. Merwin D, Nygan P, Hagg U, Yiu C, Stephan HY. Timing for effective application of anteriorly directed orthopedic force to the maxilla. *Am J Orthod Dentofacial Orthop* 1997;112:292-9.
32. Proffit WR, Fields HW Jr. Contemporary orthodontics. St Louis: Mosby; 1993; p. 456-9.
33. Haas AJ. The treatment of maxillary deficiency by opening the midpalatal suture. *Angle Orthod* 1965;16:200-17.
34. Campbell PM. The dilemma of Class III treatment. *Angle Orthod* 1983;53:175-91.
35. Haskell BS, Farman AG. Exploitation of the residual premaxillary-maxillary suture site in maxillary protraction an hypothesis. *Angle Orthod* 1985;55:108-19.
36. Haas AJ. Palatal expansion: just the beginning of dentofacial orthopedics. *Am J Orthod* 1970;57:219-55.
37. Bell RA. A review of maxillary expansion in relation to rate of expansion and patients age. *Am J Orthod* 1982;81:32-7.
38. Cozzani G. Extraoral traction and Class III treatment. *Am J Orthod* 1981;80:638-50.
39. Irie M, Nakamura S. Orthopedic approach to severe skeletal Class III malocclusion. *Am J Orthod* 1975;67:377-92.
40. Vardimon AD, Graber TM, Voss LR, Verrusio E. Magnetic versus mechanical expansion with different force threshold and point of force application. *Am J Orthod Dentofacial Orthop* 1987;92:455-66.
41. Timms DJ. Rapid maxillary expansion. Chicago: Quintessence Publishing Co; 1981.
42. Spolyar JL. The design, fabrication and use of full-coverage bonded rapid maxillary expansion appliance. *Am J Orthod* 1984;86:136-45.
43. McNamara JA Jr, Brudon WL. Orthodontic and orthopedic treatment in the mixed dentition. Ann Arbor: Needham Press Inc; 1993. p. 285-93.
44. Sarver DM, Johnston MW. Skeletal changes in vertical and anterior displacement of the maxilla with bonded rapid palatal expansion appliances. *Am J Orthod Dentofacial Orthop* 1989;95:462-6.
45. Delair J, Verdon P, Lumineau JP, Cherga-Négréa A, Talmant J, Boisson M. Note de Technique. *Rev Stomatologie* 1972;8:633-42.
46. Hickham JH. Maxillary protraction therapy and treatment. *J Clin Orthod* 1991;25:102-13.
47. Wisth PJ, Tritrapunt A, Rygh P, Bøe OE. The effect of maxillary protraction on front occlusion and facial morphology. *Acta Odontol Scand* 1987;45:227-37.
48. Roberts CA, Subtelny JD. Use of the face mask in the treatment of maxillary skeletal retrusion. *Am J Orthod Dentofacial Orthop* 1988;93:388-94.
49. Verdon P. Masque orthopédique faciale de Delaire. Tours 1986;1-20.
50. Nygan P, Hägg U, Yiu C, Merwin D, Wei SHY. Soft tissue and dentoskeletal profile changes associated with maxillary expansion and protraction headgear treatment. *Am J Orthod Dentofacial Orthop* 1996;109:38-49.
51. Kılıçoğlu H, Kırılç Y. Profile changes in patients with class III malocclusion after Delair mask therapy. *Am J Orthod Dentofacial Orthop* 1998;113:453-62.
52. Lee KG, Ryu YK, Park YC, Rudolph DJ. A study of holographic interferometry on the initial reaction of maxillofacial complex during protraction. *Am J Orthod Dentofacial Orthop* 1997;111:623-32.
53. Tanne K, Hiraga J, Kakiuchi K, Yamagata Y, Sakuda M. Biomechanical effect of anteriorly directed extraoral forces on the craniofacial complex: a study using the finite element method. *Am J Orthod Dentofacial Orthop* 1989;95:200-7.
54. Stagers JA, Germane N, Legan HL. Clinical considerations in the use of protraction headgear. *J Clin Orthod* 1992;26:87-91.
55. Ranta R. Protraction of cleft maxilla. *Eur J Orthod* 1988;10:215-22.
56. McNamara JA Jr. An orthopedic approach to the treatment of Class III malocclusion in young patients. *J Clin Orthod* 1987;21:598-608.