

CLINICAL  
SECTION

# Unilateral distalization of a maxillary molar with sliding mechanics: a case report

**A. Keles**

University of Marmara, Istanbul, Turkey

## Abstract

*Introduction* A unilateral Class II relationship could arise due to early loss of an upper second deciduous molar on one side during the mixed dentition period. This would allow the mesial drift of the molars, which may block the eruption of the second premolar.

*Methods and Results* A 15-year 8-month-old male patient presented with a Class II molar relationship on the right, and Class I canine and molar relationship on the left side. His  $\underline{E}$  was extracted when he was 5 years old. The  $\underline{5}$   $\underline{4}$  were impacted and the  $\underline{3}$  was ectopically positioned due to the space loss from the mesial migration of the  $\underline{7}$   $\underline{6}$ . In addition  $\underline{2}$   $\underline{1}$   $\underline{1}$  were in cross-bite. Skeletally he had Class III tendency with low MMPA. He presented with a straight profile and retruded upper lip. For maxillary molar distalization, a newly developed 'Keles Slider' was used. The appliance was composed of one premolar and two molar bands, and the anchorage unit was composed of a wide Nance button.  $\underline{4}$   $\underline{6}$  were connected to the Nance button and, therefore, included into the anchorage unit. The point of distal force application was close to the centre of resistance of the  $\underline{6}$  and parallel to the occlusal plane. Ni-Ti coil springs were used and 200 g of distal force was applied. Seven months later the space required for eruption of the permanent premolars and canine was regained, and the anterior cross-bite corrected. The appliance was removed and final alignment of the teeth was achieved with fixed appliances.

### Index words:

Keles Slider, molar distalization, anchorage, Class II

*Conclusions* At the end of the second phase treatment Class I molar and canine relationship was achieved on the both sides, the anterior cross-bite was corrected, inter-incisal angle was improved, and ideal overbite and overjet relationship was achieved. The active treatment time was 27 months.

Received 1 February 2001; accepted 12 July 2001

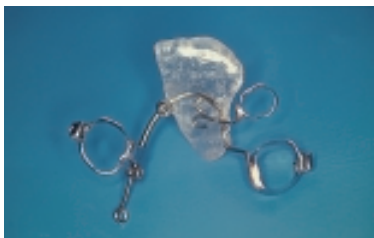## Introduction

Over the past few years non-extraction treatment and non-compliance therapies have become more popular in correction of Class II malocclusions. Treatment of Class II cases usually requires distal movement of maxillary molars in order to achieve Class I molar and canine relationship. However, if the maxillary molars are not distalized bodily and adequate anchorage is not established to move premolars and canines distally, anchorage will be lost very easily. In the literature, various types of devices have been developed for unilateral molar distalization. For many years headgear was used routinely for unilateral distal movement of maxillary molars.<sup>1–3</sup> It has been reported, however, that the asym-

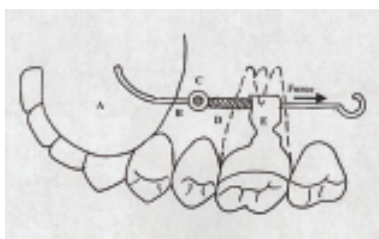
metric headgear unavoidably generates lateral forces and causes a unilateral cross-bite.<sup>4</sup> Headgear relies on patient co-operation, which makes the treatment duration unpredictable. It has also been reported that headgear is rejected by many patients because of aesthetic and social considerations.<sup>5</sup>

The difficulties of headgear wear and dependence on patient co-operation stimulated many investigators to develop new intra-oral devices and techniques for distal movement of molars. These include magnets<sup>6–8</sup> and super-elastic Ni-Ti coil springs.<sup>9–11</sup> The Pendulum appliance<sup>12</sup> and the Intra Oral Bodily Molar Distalizer<sup>13</sup> were developed for the same purpose. However, it would appear from the literature that other than with a few appliances, bodily molar distalization could not be

regularly achieved bodily. The aim of this case report is to illustrate a method of regaining the space for eruption of impacted 54 by distalization of 76 without tipping.



**Fig. 1** Occlusal view of the Keles slider



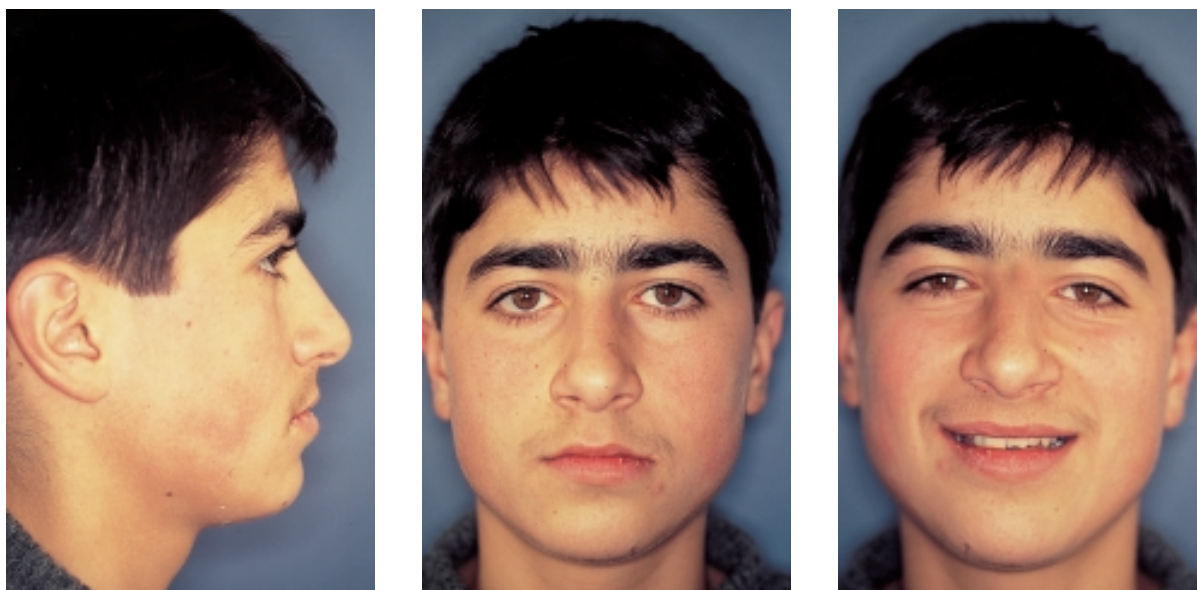**Fig. 2** Biomechanics of force system of Keles Slider. Distal force is applied at the level of centre of resistance of maxillary first molar. (A) Acrylic anterior bite plane. (B) 0.036-inch diameter wire rod for distal sliding of maxillary first molar. (C) Adjustable screw for activation of the coil spring. (D) 0.036-inch heavy Ni-Ti open coil spring. (E) Special tube soldered to the first molar band.

## Appliance construction

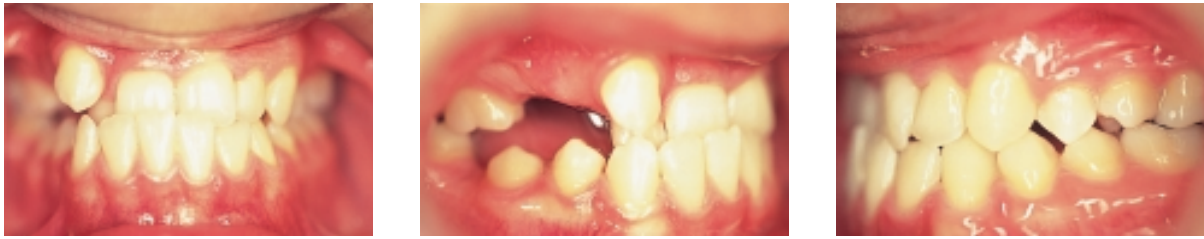
For molar distalization a new appliance was developed 'The Keles Slider' (patent applied for). 64 6 were banded. On the palatal side of 6 band a 0.45-inch diameter tubes was soldered (Leone, Firenze A 0761-45). 4 6 bands were attached with 1.1 mm in diameter stainless steel retaining wires to an acrylic Nance button (Figure 1). On the palatal side of 6 0.9 mm diameter stainless steel wire was embedded into the acrylic about 5 mm apical to the gingival margin of the molar, which passed through the tube and was oriented parallel to the occlusal plane. For molar distalization 0.9 mm in diameter heavy Ni-Ti coil spring was placed in between the Gurin lock (3M Unitek, USA, 560-400) on the wire and the tube in full compression. The amount of force generated with the full compression of the 2 cm open coil was about 200 g. This force system would allow consistent force at the centre of resistance of 6. Biomechanics of the force system is presented in Figure 2. Patients were seen once every month and the screw was activated with the use of a Gurin lock wrench (3M Unitek, USA, 810-002). After the distalization, the Keles Slider was maintained in the mouth until the permanent premolars fully erupt.

## Case history

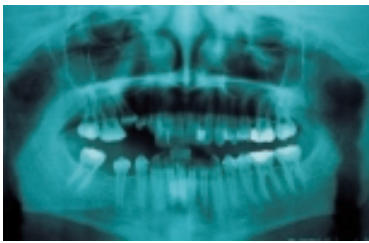
T.V. is a 15 years 8-month-old male diagnosed with a mutilated dentition due to the early loss of E. He pre-



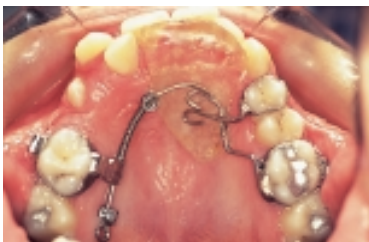**Fig. 3** (a-c) Extra-oral view of T.V. before the distalization.



**Fig. 4** (a–c) Intra-oral view of T.V. before the distalization.



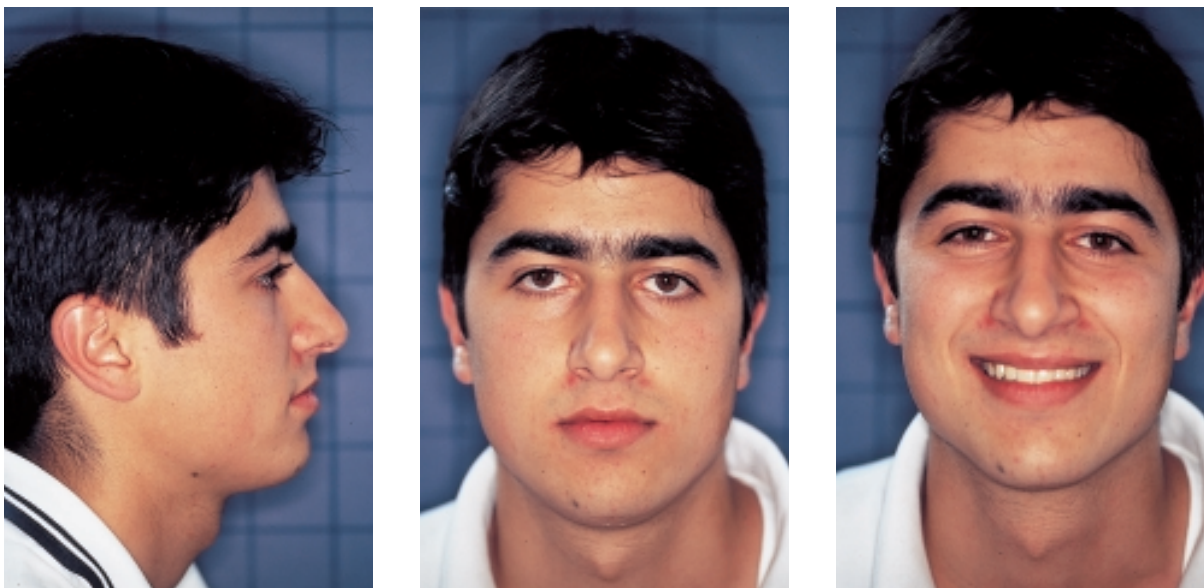**Fig. 5** Panoramic radiograph of T.V. before the treatment.



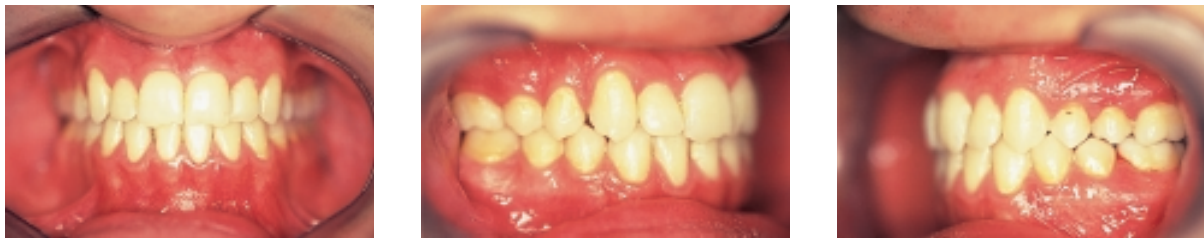**Fig. 6** Occlusal view of the Molar Slider after the cementation.

sented with a slightly retruded upper lip and obtuse naso-labial angle (Figure 3a–c). Skeletally, he presented Class III tendency and low angle skeletal pattern. His intra-oral pictures are presented at (Figure 4a–c). His  $\overline{7} \overline{6}$  severely migrated mesially and prevented the eruption of the  $\underline{5} \underline{4}$  (Figure 5). His  $\overline{6}$  was extracted earlier due to a deep carious lesion. He had anterior cross-bite on the right side and ectopic  $\overline{3}$ . On the left side Class I molar and canine relationship was present.

Our treatment was non-extraction and unilateral molar distalization for regaining space for the eruption of impacted premolars and alignment of ectopic  $\overline{3}$ . The Keles Slider was cemented (Figure 6). After the activation of the Keles Slider, 5 mm of distalization was achieved. The anterior cross-bite was corrected with the protrusion of the incisors by the reciprocal mesial force generated by the Keles Slider. The distalization process lasted for 7 months. Fixed orthodontic therapy was then instituted. At the end of the second stage orthodontic



**Fig. 7** (a–c) Extra-oral view of T.V. at the end of the fixed orthodontic treatment.



**Fig. 8** (a–c) Intra-oral view of T.V. at the end of the fixed orthodontic treatment.

treatment Class I molar and canine relationship, and ideal overbite and overjet relationship were achieved on both sides. The profile was improved by the protrusion of the upper lip. Extra- and intra-oral pictures at the end of the fixed treatment are presented at Figures 7a–c and 8a–c.

## Conclusions

The results demonstrated that for this patient the Keles Slider was an effective device to distalize molars bodily and open up the space for eruption of permanent premolars. The anterior cross-bite was corrected with the reciprocal mesial vector of the force generated by the appliance. The other advantage of this appliance was the ease of reactivation and short chairside time. It appeared that guided consistent distal force at the level of centre of resistance allowed the molars to slide distally, without tipping, and enabled the premolars to erupt freely.

## References

1. Haack DC, Weinstein S. The mechanics of centric and eccentric cervical traction. *Am J Orthod Dentofacial Orthop* 1958; **44**: 236–257.
2. Oosthuizen L, Dickman JFP, Evans WG. A mechanical appraisal of the Kleochn extraoral assembly. *Angle Orthod* 1973; **43**: 221–232.
3. Baldini G. Unilateral headgear: Lateral forces as unavoidable side effects. *Am J Orthod Dentofacial Orthop* 1980; **77**: 333–339.
4. Yoshida N, Jost-Brinkmann P, Miethke R, König M, Yamada Y. An experimental evaluation of effects and side effects of asymmetric face bows in the light of *in vivo* measurements. *Am J Orthod Dentofacial Orthop* 1998; **26**: 706–714.
5. Egolf RJ, BeGole EA, Upshaw HS. Factors associated with orthodontic patient compliance with intraoral elastic and headgear wear. *Am J Orthod Dentofacial Orthop* 1990; **97**: 336–48.
6. Blechman AM, Smiley H. Magnetic force in orthodontics. *Am J Orthod Dentofacial Orthop* 1978; **74**: 435–443.
7. Gianelly AA, Bonds PW, Johnson WM. Distalization of molars with repelling magnets. *J Clin Orthod* 1988; **22**: 40–44.
8. Bondemark L, Kurol J. Distalization of maxillary first and second molars simultaneously with repelling magnets. *Eur J Orthod* 1992; **14**: 264–272.
9. Gianelly AA, Bednar J, Dietz VS. Japanese Ni-Ti coils used to move molars distally. *Am J Orthod Dentofacial Orthop* 1991; **99**: 564–566.
10. Bondemark L, Kurol J. Repelling magnets versus superelastic Ni-Ti coils in simultaneous distal movement of maxillary first and second molars. *Angle Orthod* 1994; **63**: 189–198.
11. Carano A, Testa M, Siciliani G. The lingual distalizer system. *Eur J Orthod* 1996; **18**: 445–448.
12. Hilgers JH. The pendulum appliance for Class II non-compliance therapy. *J Clin Orthod* 1992; **26**: 706–714.
13. Keles A, Sayinsu K.A. New approach in maxillary molar distalization: Intraoral bodily molar distalizer. *Am J Orthod Dentofacial Orthop* 2000; **117**: 39–48.