

## **Bodily Distalization of Molars with Absolute Anchorage**

**Ahmet Keles, DDS, DMSc<sup>a</sup>; Nejat Erverdi, MD, DDS<sup>b</sup>; Serdar Sezen, MD, DDS<sup>c</sup>**

**Abstract:** Palatal implants have been used over the last two decades to eliminate headgear wear and to establish stationary anchorage. In this case report, the stability of a palatal implant for distalization of molars bodily and for anchorage maintenance was assessed. The implant was a stepped screw titanium (4.5 mm diameter × 8 mm length), and it was placed in the palatal region for orthodontic purposes. A surgical template containing a metal drill housing was prepared. Angulation of the drill housing was controlled according to the radiologic tracing of the maxilla transferred to a plaster cast section in the paramedian plane. The implant was placed using a noninvasive technique (incision, flap, and suture elimination) and left transmucosally to facilitate the surgical procedure and to reduce the number of operations. The paramedian region was selected (1) to avoid the connective tissues of the palatine suture and (2) because it is considered to be a suitable host site for implant placement. After three months of healing, the implant was osseointegrated and orthodontic treatment was initiated. For molar distalization, the Keles Slider appliance was modified and, instead of a Nance button, a palatal implant was used for anchorage. The results showed that the molars were distalized bodily at five months, and no anchorage loss was observed. At the end of the treatment, the smile was improved, and an ideal Class I molar and canine relationship, an ideal overbite, and an ideal overjet were all achieved. In conclusion, palatal implants can be used effectively for anchorage maintenance and in space-gaining procedures. Use of a three-dimensional surgical template eliminated implant placement errors, reduced chair time, minimized trauma to the tissues, and enhanced osseointegration. This method can be used effectively to achieve distalization of molars bodily without anchorage loss. (*Angle Orthod* 2003;73:471–482.)

**Key Words:** Keles Slider; Palatal implant; Noncompliance therapy; Molar distalization; Anchorage; Class II malocclusion

### **INTRODUCTION**

Class II malocclusion is one of the most difficult malocclusions to treat, and stationary anchorage is one of the main factors determining the success of the treatment. Conventional extraoral appliances are routinely used to establish maximum anchorage. However, many patients reject headgear wear because of social and esthetic concerns, and the success of this treatment solely depends on patient cooperation.<sup>1</sup> In many cases, a lack of cooperation results in anchorage loss, and unsatisfactory treatment results. Another

disadvantage in the use of headgear wear is the possibility of creating serious facial injuries.<sup>2,3</sup>

The difficulty in the use of headgear wear has motivated many investigators to develop the mechanics of intraoral molar distalization. Some investigators have used the Nance appliance to obtain anchorage from the palate; however, in most of these studies anchorage loss was unavoidable, and reduced hygiene under the acrylic resin button created inflammation of the soft tissue.<sup>4–7</sup>

In recent years, studies have been directed toward the use of osseointegrated implants as anchorage units.<sup>8–13</sup> Experimental biomechanical studies,<sup>14,15</sup> studies on animal models,<sup>15–20</sup> and clinical investigations<sup>21–23</sup> have shown that dental implants that were placed in the alveolar bone were resistant to the orthodontic force that was applied. However, patients who need orthodontic treatment generally have a complete dentition; thus, there are no available sites for implant placement. Thus, alternative anatomic sites are required, and some investigators have used the retromolar area<sup>11,24</sup> or palatal region<sup>25–30</sup> as alternative sites. Ohmae et al,<sup>31</sup> in an animal model, and Umemori et al,<sup>32</sup> in humans, applied titanium mini plates to the mandibular corpus area and used them as anchorage for the intrusion of mandibular

---

<sup>a</sup> Associate Professor, Department of Orthodontics, Faculty of Dentistry, Marmara University, Istanbul, Turkey

<sup>b</sup> Professor and Head, Department of Orthodontics, Faculty of Dentistry, Marmara University, Istanbul, Turkey

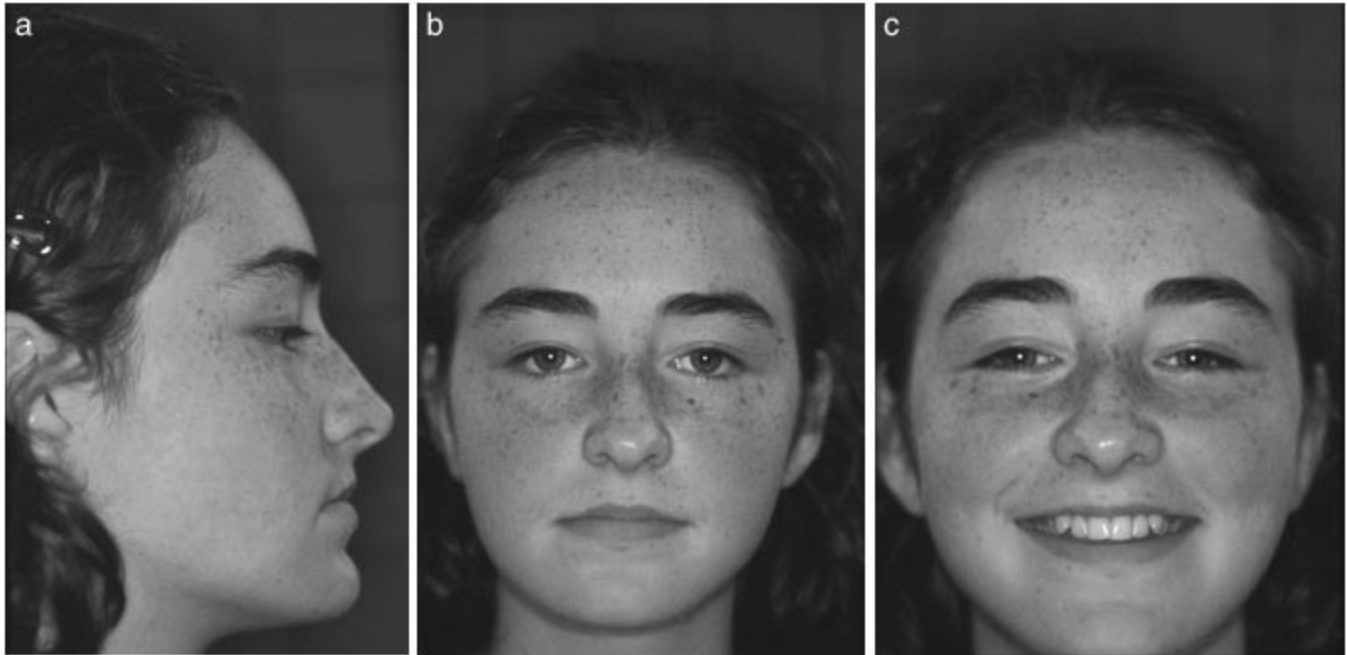<sup>c</sup> Research fellow, Department of Orthodontics, Faculty of Dentistry, Marmara University, Istanbul, Turkey

Corresponding Author: Ahmet Keles, DDS, DMSc, Director of Orthodontic Clinic, University of Connecticut Health Center, Farmington, CT 06030-2105

(e-mail: keles@ortodonti.com).

Accepted: October 2002. Submitted: August 2002.

© 2003 by The EH Angle Education and Research Foundation, Inc.



**FIGURE 1.** (a) Initial extraoral profile view of the patient. (b) Initial extraoral frontal view of the patient. (c) Initial extraoral view of smile of the patient.

posterior segment. Both reported that they achieved effective intrusion of the mandibular posterior dentoalveolar segment and corrected anterior open-bites. Some investigators used plates at the zygomatic region as absolute anchorage for open-bite corrections and canine distalization.<sup>33</sup>

Use of palatal implants for orthodontic anchorage is a new area of research, and investigations on this subject are limited. The orientation of palatal implants, in contrast to conventional dental implant applications in the maxilla, is in a reverse inclination. This reverse angulation of the long axis of the implant can misguide the surgeon in implant positioning and create a certain difficulty during surgical placement. Recently, for precise and easy palatal implant placement, a new method was introduced.<sup>34</sup> In this case report, the stability of a palatal implant for molar distalization and anchorage maintenance is assessed.

## MATERIALS AND METHODS

### Case history

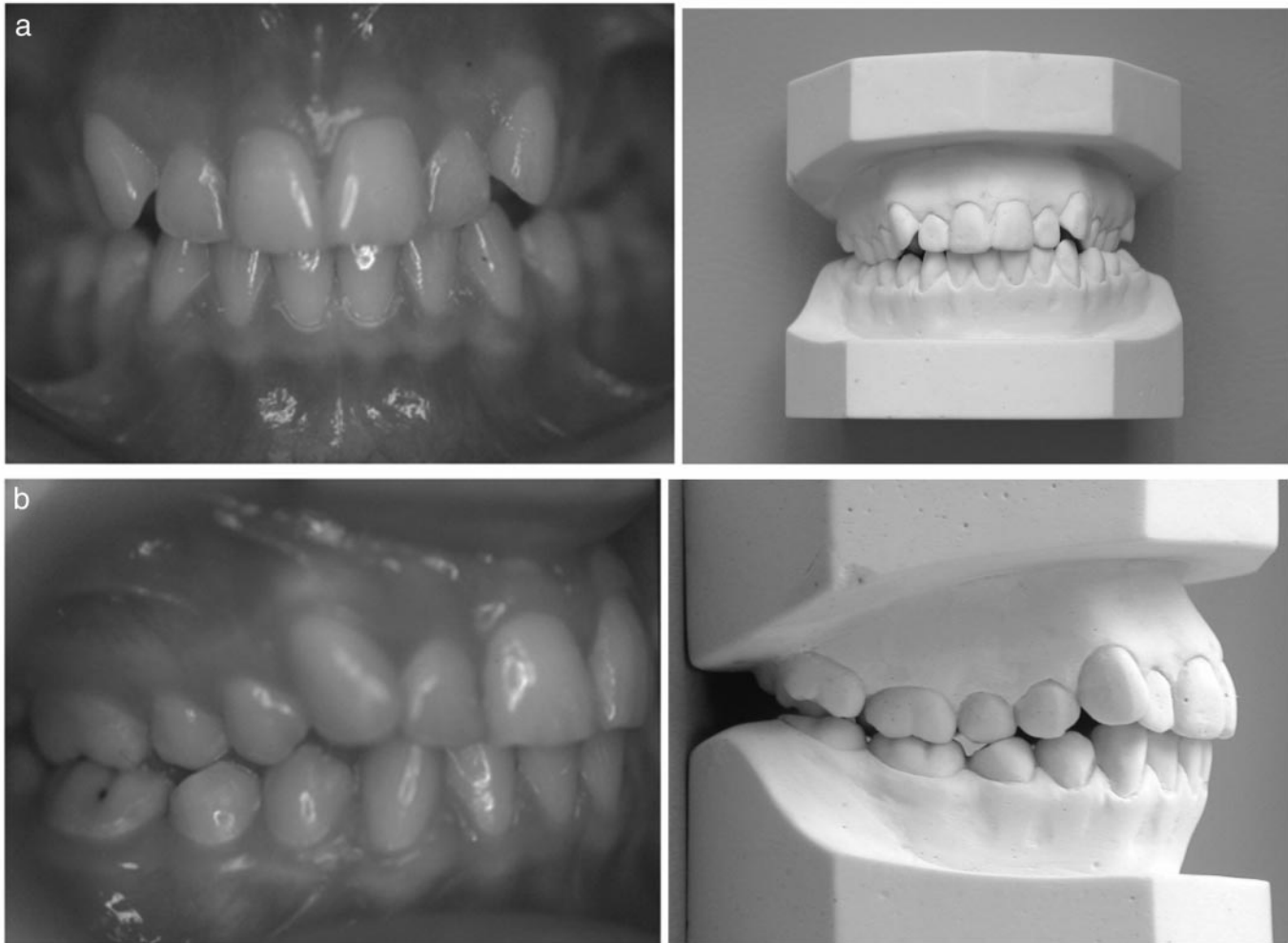
ZA was a 17-year, 6-month-old female diagnosed with Class II Division 1 malocclusion. She presented a pleasant straight profile, but when she smiled her maxillary canines appeared unpleasant (Figure 1a through c). Her chief complaint was buccally positioned maxillary canines (Figure 2a through d). She presented an end on molar relationship on the right side and a Class II molar relationship on the left side (Figure 2b,c). She had six mm of crowding in the maxilla and four mm in the mandible, with posterior dental constriction on both sides.

Our treatment plan was palatal implant placement for anchorage and molar distalization to correct the Class II and to resolve the maxillary crowding. A stepped screw titanium implant (4.5 mm diameter  $\times$  8 mm length) (Frialit-2 Implant System, Synchro Screw implants, Friadent GmbH, Mannheim, Germany) was placed in the palatal region for orthodontic purposes.

### Radiological evaluation and implant positioning

For precise palatal implant placement, the method described by Tosun et al<sup>34</sup> was used. Lateral cephalograms with maxillary templates were obtained. The acrylic resin template contained a spherical metal marker at the highest point of the palate. The purpose of using these templates was to calculate magnification of the radiograph to assess the exact dimensions of the bone as well as to create a sagittal reference point for identifying the location of the drilling site for implant placement.

Radiological evaluation of the palatal bone morphology, determined the path for the placement of the implant. In the transverse plane, the implant was not placed directly into the midpalatal suture that consisted of connective tissue. Rather, the lateral side of the palatal suture (paramedian region) was chosen as the implant bed to increase retention by the bony. There was enough bone volume to place an implant in a triangle formed by the nasal cavity, incisor roots, and palate—but these anatomic structures were close to each other; thus, there was also a risk of penetration or damage to these anatomic structures while placing the implant.

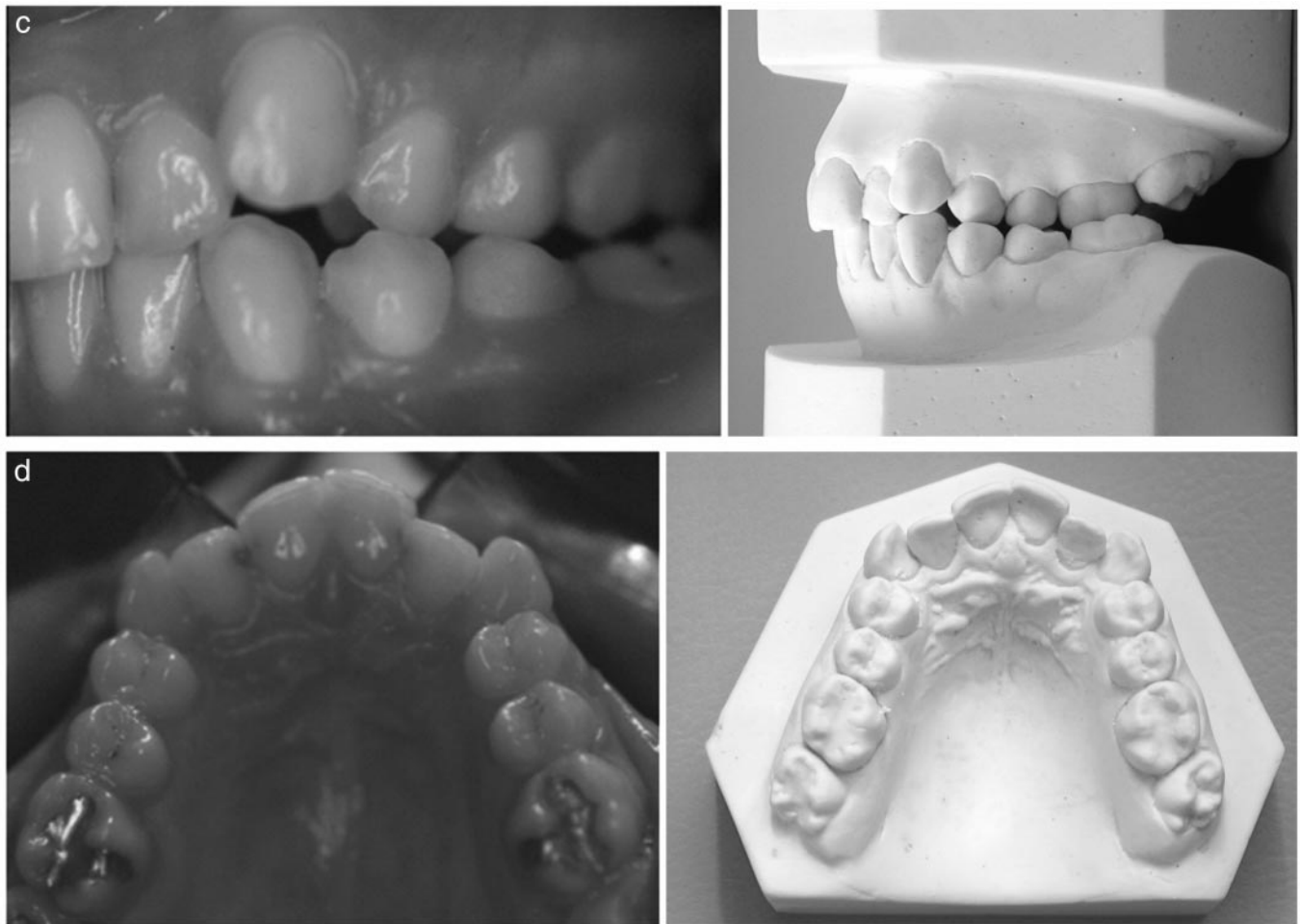


**FIGURE 2.** (a) Initial intraoral frontal view of the patient (Please note ectopic maxillary canines). (b) Initial intraoral right view of the patient.

To avoid such a risk, we used a surgical template to guide the implant along the path determined by the radiological evaluation. The plaster cast used for template preparation was cut along the paramedian line passing through the mesial aspect of the central incisor. On the lateral cephalogram, the radiographic view of the maxilla and central incisor was traced and then cut along the pencil line and carried to the paramedian section of the plaster cast. A drill insertion hole was prepared in the acrylic resin template using a stainless steel bur of 2.5-mm diameter. A cylindrical metal housing, 7 mm in length and 2.1 mm in diameter, containing a pilot drill was placed into the implant access hole. The drill housing was fixed by orthodontic acrylic resin according to the desired implant inclination by controlling it on the plaster model section. In the transverse plane, approximately one mm from the palatine suture and in the parasagittal plane, a palate-nasal spine path was used to avoid root tip and nasal cavity perforations. Thus, a three-dimensional surgical template for accurate implant angulation was obtained (Figure 3a,b).

### Surgical method

The three-dimensional surgical template was placed in the mouth to mark the implant location. A pilot drill was applied through the metal housing in the template. After that, the mucosa was removed using a punch drill, and the standard surgical protocol for placing the chosen implant system was followed. Drilling was carried out at 1000 rpm under internal and external sterile saline cooling. Drills with eight-mm-long stoppers were used in the following order: a pilot drill of 2.0-mm diameter, a twist drill of 3.0-mm diameter, and finally a spade drill of 4.5-mm diameter. The implant was placed transmucosally to avoid a second surgery and to facilitate impression and laboratory procedures. The implant was not loaded with any force for a minimum of three months. After the healing period, impressions were made using a conventional technique for transferring the impression post and molar bands to a plaster cast. An orthodontic abutment (Friadent GmbH) was fixed to the implant analog on the plaster.



**FIGURE 2.** Continued. (c) Initial intraoral left view of the patient. (d) Initial intraoral upper occlusal view of the patient.

Cephalograms were obtained after a healing period of three months to detect the presence of any radiolucent area in the peri-implant bone. Percussion by a metal probe was used to evaluate implant mobility. Peri-implant soft-tissue health at each recall was recorded using the modified plaque index<sup>35</sup> and a modified sulcus bleeding index.<sup>36</sup>

### Appliance construction


For molar distalization, Keles Slider appliance (patent pending)<sup>37-39</sup> was modified and, instead of using a Nance button for anchorage, the anchorage was obtained from the palatal implant. This modification in the design eliminated the support of the palatal soft tissues, first premolars, and anterior teeth. Maxillary first molars were banded, and on the palatal side of the first molar bands, tubes of 0.045-inch diameter were soldered (Leone A076-45, Firenze, Italy). A stainless steel wire of 0.040-inch diameter was attached to the palatal implant and the wire oriented about five mm apical to the gingival margin of the first molars, which passed through the tube and oriented parallel to the occlusal plane. A Ni-Ti coil spring (Leone C1210-45), two cm

length, 0.045-inch diameter, and 0.010-inch thickness, was placed in between the lock on the wire and the tube in full compression for molar distalization. The amount of force generated with the full compression of the two cm open coil was about 200 gm. This force system would allow application of consistent force at the level of the center of resistance of the first molars. The biomechanics of the force system is presented in Figure 4. The patient was seen once every month, and a Gurin lock (3M Unitek, Orthodontic Products, Monrovia, Calif., 560-400) was activated with the Gurin lock wrench (3M Unitek, 810-002). After the distalization, the coil springs were removed, the locks were tightened and flushed to the tubes of the molar bands.

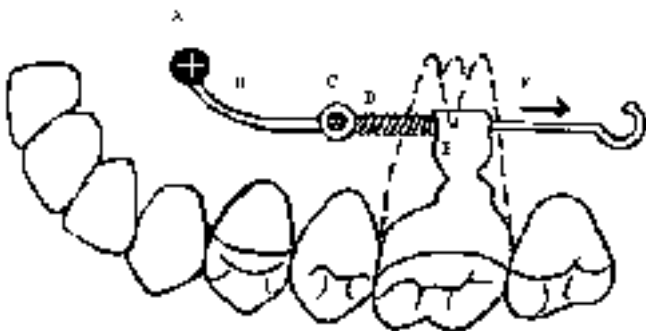
### RESULTS

After the three-month healing period, neither a peri-implant radiolucent layer on the cephalometric radiograph nor an implant mobility was detected. Thus, the implant was considered to be osseointegrated and was loaded with orthodontic forces.

Orthodontic treatment results showed that the maxillary



**FIGURE 3.** (a) Lateral view of plaster cast section with a tracing and surgical template with drill housing containing a pilot drill. (b) Frontal view of plaster cast section and surgical template with drill housing containing a pilot drill. (Please note the inclination of the drill through the paramedian region.)



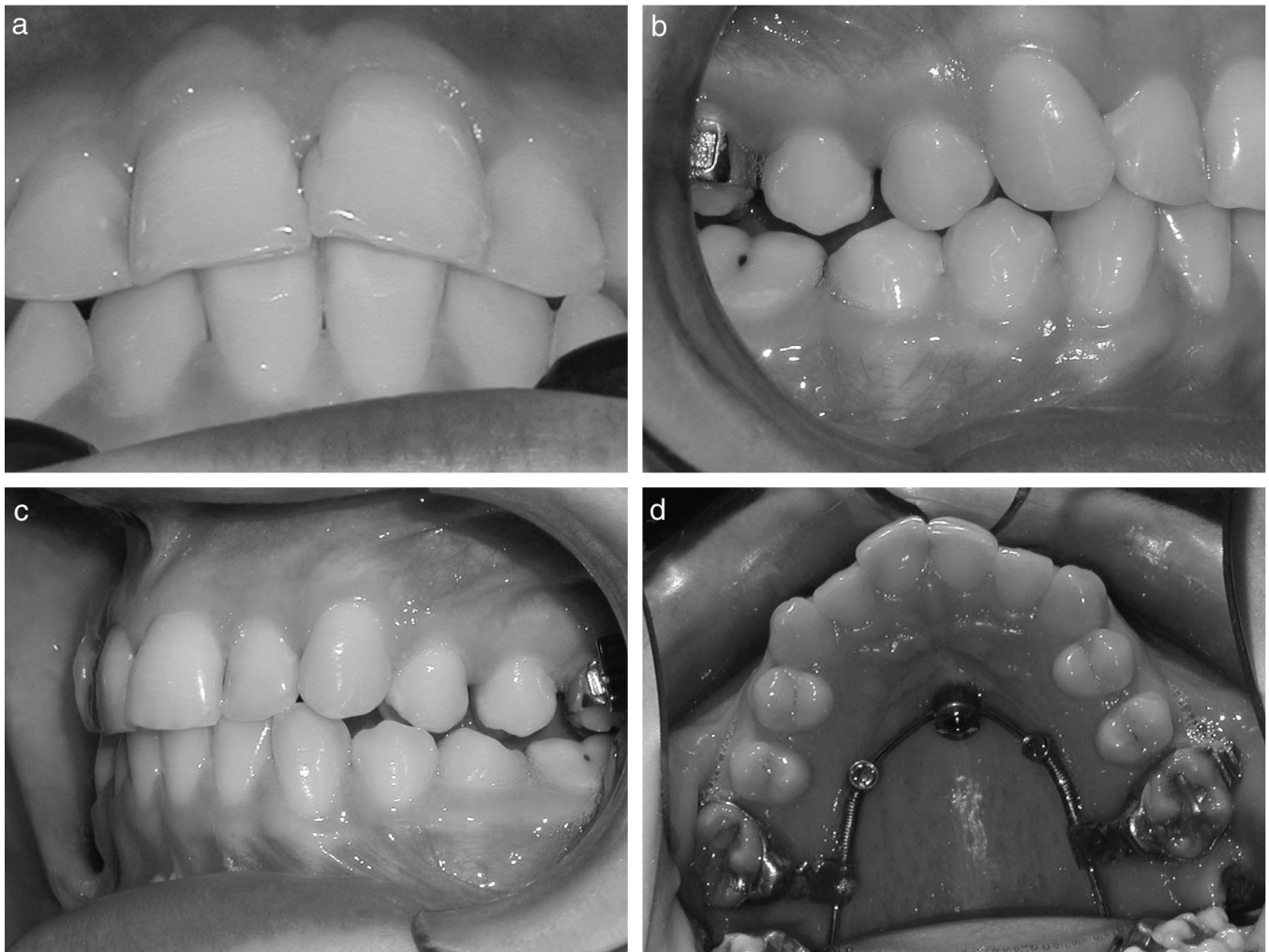
**FIGURE 4.** Biomechanics of the Modified Keles Slider. Palatal implant; 0.040-inch stainless steel rod; Gurin lock; Heavy Ni-Ti coil spring; 0.045-inch tube that was soldered to the first molar band.

molars distalized by three mm on both sides five months after the cementation of the appliance (Figure 5a through d). A super-Class I relationship was achieved on both sides, and the maxillary first and second premolars drifted distal-

ly. This allowed the crowded and ectopically positioned maxillary canines to align into a Class I relationship with the help of the transeptal fibers and distal drift. Molars were distalized in a bodily fashion (Figure 6a,b), and there was no anchorage loss at the anterior segment with no upper incisor proclination or increase of the overjet (Figures 5a, 6b, and 7). The coil springs were removed, and the locks were flushed to the mesial side of the molar tubes thus converting the appliance into a passive anchorage appliance (Figure 8).

Second stage-fixed orthodontic therapy was initiated and lasted 12 months. Three months before the end of the fixed orthodontic treatment, the palatal implant was easily removed by loosening the implant with the help of a hollow drill (Figure 9a,b). The implant site healed rapidly within five days. One month later, there was no scar tissue on the palate, and the palatal cortical bone bridge appeared (Figures 10 and 11).

At the end of the treatment, a pleasant profile was pre-



**FIGURE 5.** (a) Upper incisors did not procline, and the overjet did not increase after the distalization. (b) Super-Class I relationship was achieved in five months, and the premolars were drifted distally with the help of transeptal fibers, ectopic maxillary canines got into the arch (right view). (c) Super-Class I relationship was achieved in five months, and the premolars were drifted distally with the help of transeptal fibers, ectopic maxillary canines got into the arch (left view). (d) Ectopic maxillary canines got into the arch with the distal drift of the first premolars and the stretch of transeptal fibers (occlusal view).

sent, the smile was improved, and an ideal Class I molar and canine relationship, an ideal overbite, and an ideal overjet were all achieved. Extraoral and intraoral pictures of the patient at the end of the fixed orthodontic treatment and the cephalometric values and superimpositions are presented in Figures 12 through 14 and in Table 1.

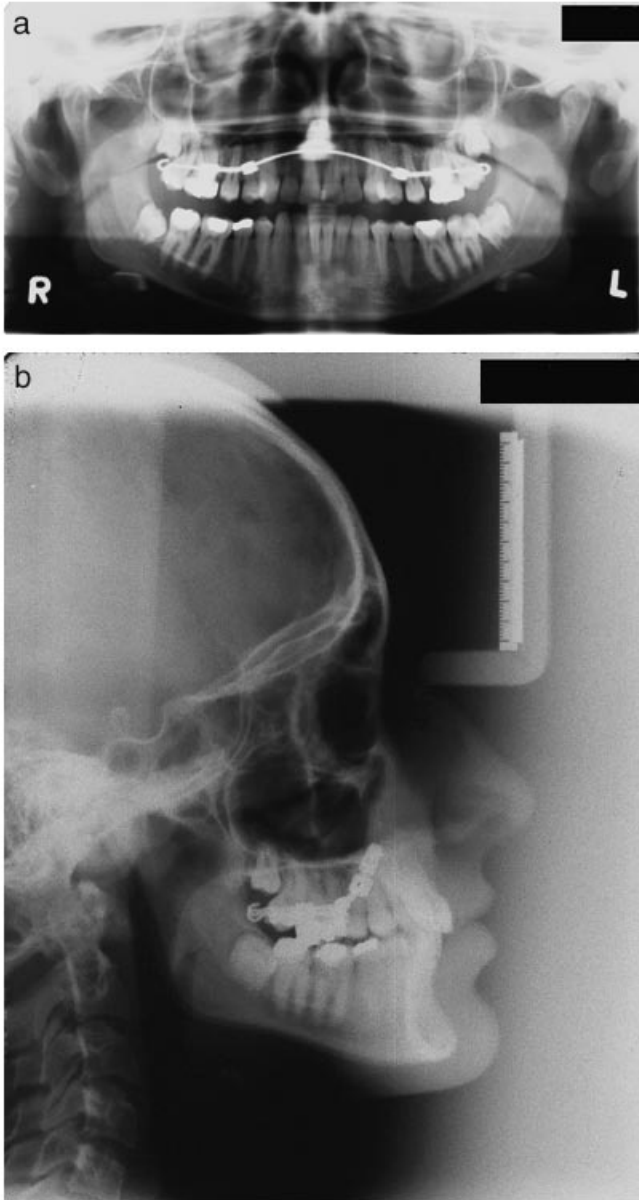
## DISCUSSION

The use of palatal implants has become an alternative mode of treatment in orthodontics over the last two decades.<sup>25-30</sup> The esthetic and social concerns of the use of headgear wear for molar distalization and the anchorage loss that occurs with the application of intraoral molar distalization mechanics stimulated many investigators to use palatal implants for anchorage. This treatment option can be criticized as necessitating surgery for a transient implant.

But the benefits of this treatment, in comparison with those of the conventional treatment that uses headgear or intraoral appliances, are significant. The major advantage of using palatal implants is the preservation of the anchorage while moving the molars distally.

For molar distalization, the Keles Slider appliance was modified. To preserve the anchorage, a Nance button and first premolar bands were eliminated; instead, the wire rod for molar distalization was connected directly to the palatal implant. This modification in the design also allowed distal drift of the first and second premolars with the help of the transeptal fibers while moving the molars distally.

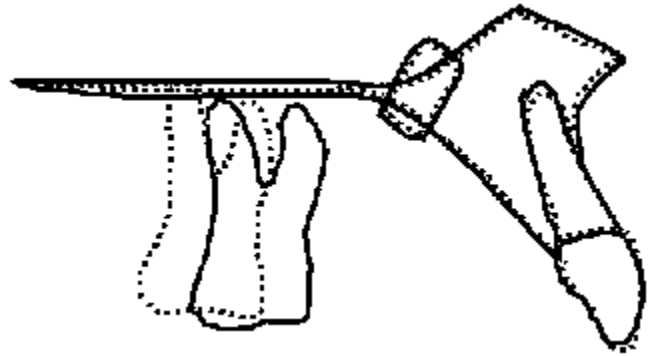
Our results showed that the implant was stable after the application of orthodontic forces, there was no anchorage loss in the anterior segment, and the molars were distalized bodily by three mm on both sides. In our patient, third



**FIGURE 6.** (a) Bodily distal movement of first molars with the application of force closer to the center of resistance of the first molars (please note distal drift of second and first premolars). (b) Bodily distal moment of the first molars with the application of force closer to the center of resistance of the first molars (please note the incisors were not proclined).

molars were present on both sides. In fact, if more than two-to three-mm distalization is required, we recommend the extraction of the third molars before the distalization.

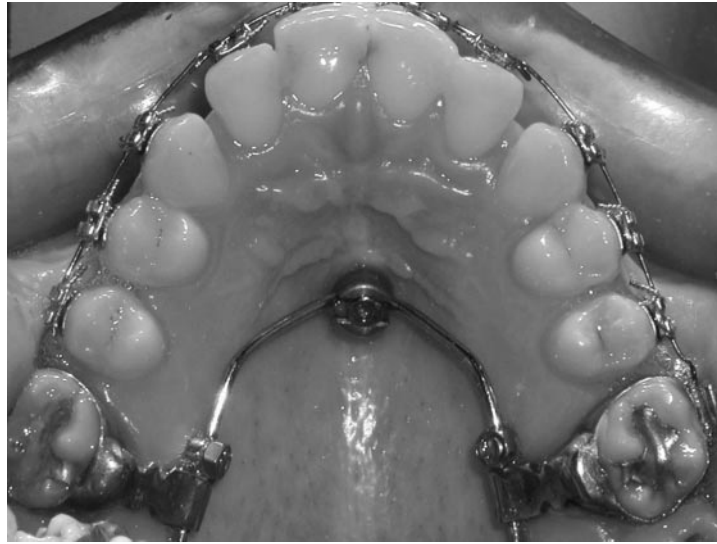When a minimally invasive placement technique that eliminates the incision, flap, and sutures is combined with a one-stage surgery, the surgical approach is simplified and well tolerated by patients. The patient's acceptance regarding surgical effects was positive, and postoperative pain and discomfort symptoms were negligible.



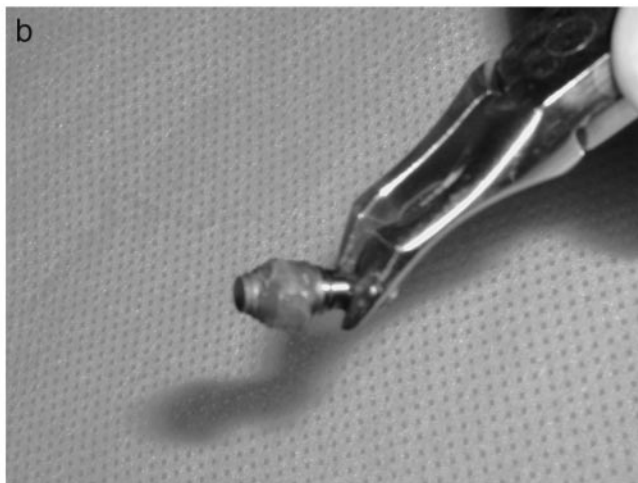
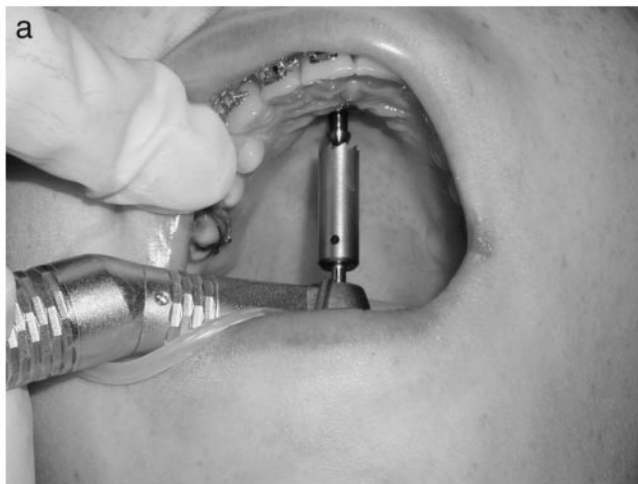
**FIGURE 7.** Cephalometric superimposition of the maxilla that shows the dental changes in the maxilla. Solid line = after the distalization, dotted line = after the distalization.

Bernhatr et al<sup>36</sup> used the conventional surgical procedure ad modum Branemark for the placement of palatal implants. This conventional implant surgery requires a full-thickness flap with considerable extension to view the operation field. For implant placement in alveolar bone, this requirement is helpful for detecting possible dehiscences or fenestrations around the implant and facilitates decisions concerning implant angulation and diameter. With palatal implants, the surgical procedure can be simplified by the elimination of the incision, flap raising, and sutures because the operating field in the palate is a quasiflat surface and there is no risk of creating defects in the bone around the implant. Thus, a punch drill can perforate the mucosa overlying the already decided implant site. This can decrease operation time, postoperative complications, edema, and pain. As the palatal mucosa is highly keratinized, peri-implant soft-tissue conditions are favorable, creating a firm connective tissue sealing. Thus, there is no risk in allowing the implant to heal transmucosally. Transmucosal palatal implants cannot be disturbed by chewing forces and are not preloaded because of their central localization. In the present study, the implant neck was not totally embedded into the cortical level but rather at the mucosal level to achieve one-stage advantages. The findings of another one-stage orthodontic implant system study also confirmed these results.<sup>29,30</sup> At the conclusion of the orthodontic treatment, surgical attempts can be made to cover the implant using punched mucosa or sliding flaps. In the present study, the implant was removed with a hollow drill and a reverse torque using extracting forceps, and the implant socket was left to heal without further treatment.

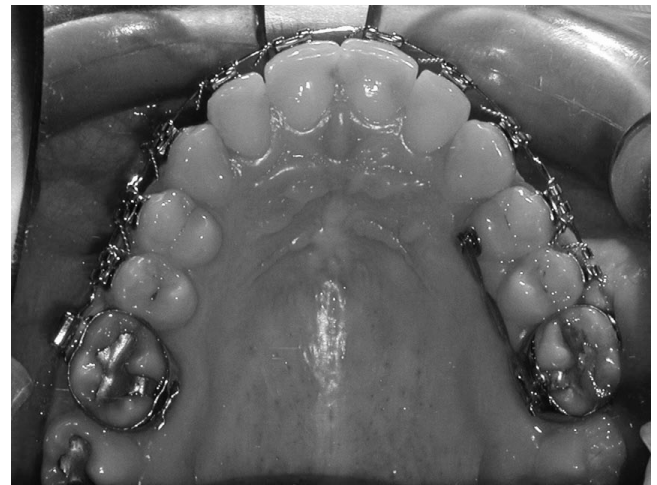Major difficulties in the treatment involved the nonconventional angulation that occurs during the positioning of the implant, which can misguide the surgeon. The reverse inclination of the impression posts from the pharyngeal direction makes a normally easy procedure a time-consuming step. Primary stability is a prerequisite in implant dentistry. In the present study, lateral angling of the implant was performed to avoid placement into the connective tissues of



**FIGURE 8.** After the distalization, the appliance is converted to passive holding arch (please note the removal of the coil springs).



**FIGURE 9.** (a) Application of the hollow drill to remove the implant. (b) The removed palatal implant.

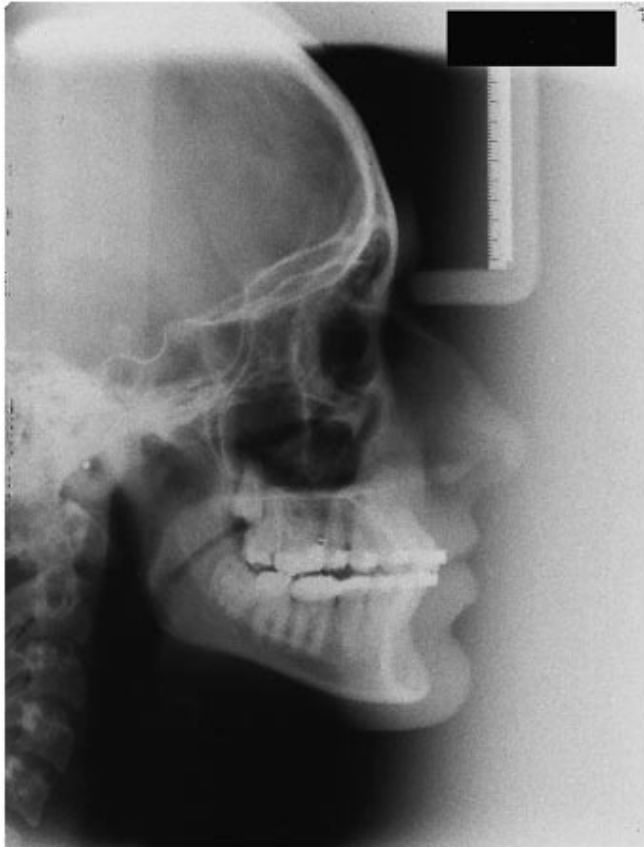


**FIGURE 10.** Rapid healing of the implant site (occlusal view).

the palatine suture and to obtain more retention in the bone, as shown in the study of Bernhatr et al<sup>36</sup> This lateral angling of the implant also facilitates viewing and handling of the handpiece.

To eliminate mistakes in the radiologic evaluation of the pertinent anatomic structures, the use of a template is mandatory. Because of cephalometric radiograph magnification, metallic markers were used, and they served as a dimensional reference to assess the exact dimensions on the radiograph and to select the implant of correct size. The same template also can be used for treatment planning on the plaster cast and as a surgical template during surgery to facilitate preparation of the implant bed. In the preparation of the surgical template, attention was paid to directing the drill housing from the palate toward the nasal spine. The drill housing was angled at about 30° in the frontal plane.

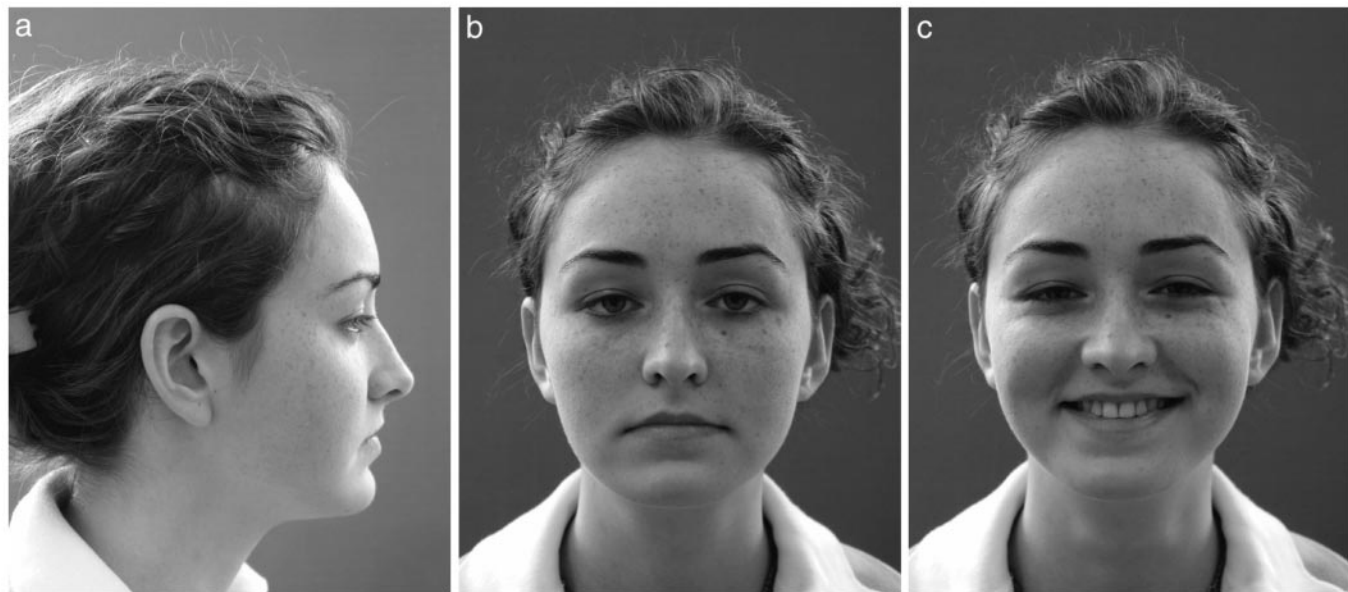



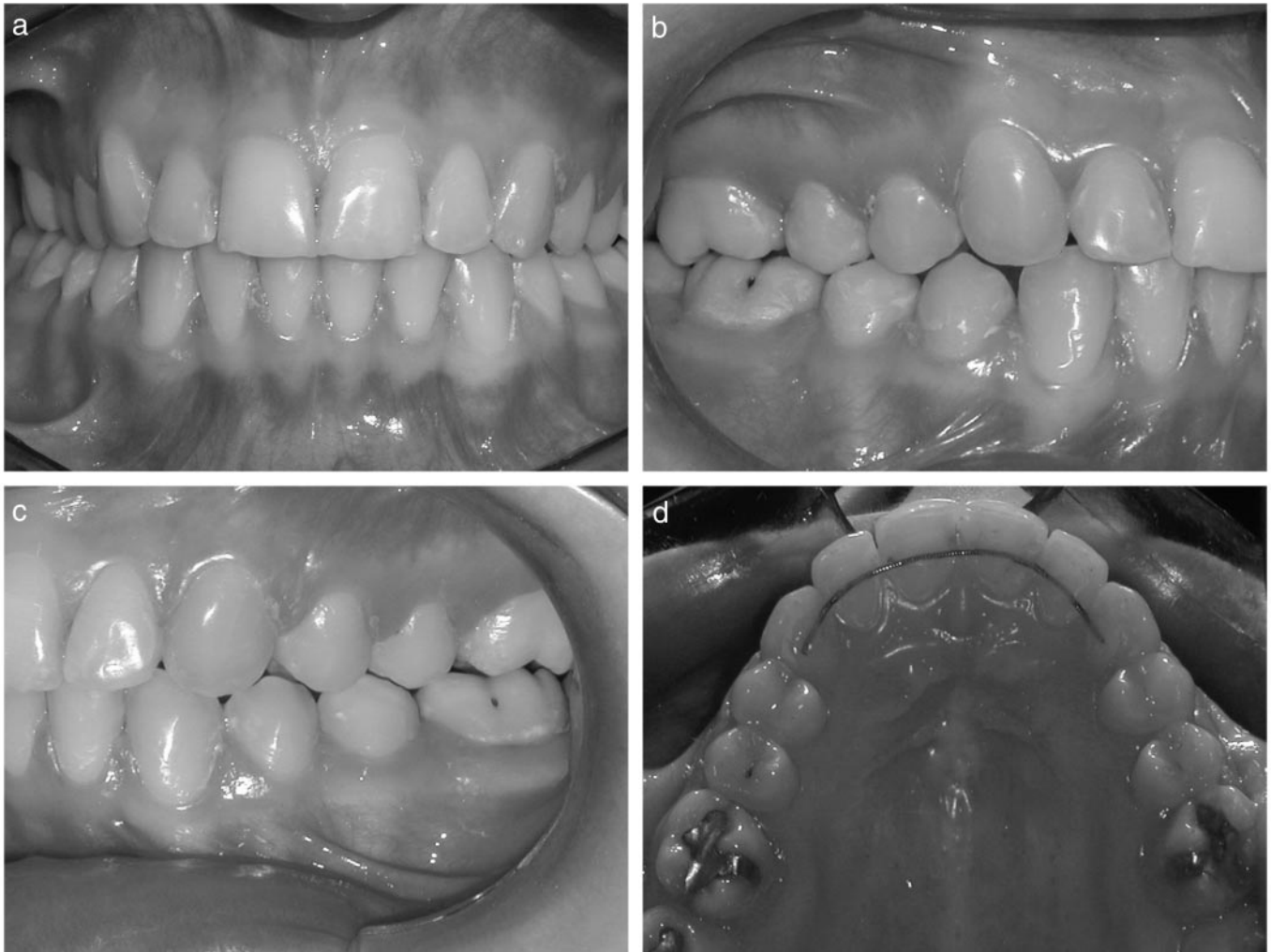
**FIGURE 11.** Cephalometric radiograph that shows the healing of the implant site (please note the cortical bone bridge formation at the implant site).

**TABLE 1.** Cephalometric Values of the Patient Before and After Treatment

Measurements	Normal	Initial	Final
Go-Me-Sn	32 ± 8°	30	30
Saddle angle	123 ± 5°	127	124
Articular angle	143 ± 6°	141	142
Gonial angle	130 ± 7°	125	126
Σ	396 ± 3°	393	392
Jarabak	59–62	56	59
ANSMe/NM	55	53	54
Maximum height	60°	60	61
Facial axis angle	90°	91	91
FMA	25°	18	21
Y-axis angle	59.4°	55	55
SNA	82 ± 2°	81	82
SNB	80 ± 2°	79	80
ANB	2°	2	2
Witt's appraisal	-1.0 mm	1	2.5
SL	51 mm	54	57
SE	22 mm	18	16
Nper-PA	-1 mm	3	3
Maximum depth	90°	88	89
⊥-SN	103°	103	101
⊥-NA	22°	21	18
⊥-NA	4 mm	4	3
⊥-FH	112°	115	110
IMPA	90°	87	90
I-NB	25°	25	21
I-NB	4 mm	5	4
Pog-NB	4 mm	5	5
Holdaway ratio	1/1	1	0.8
⊥-I	131°	133	138



**FIGURE 12.** (a) Final view of extraoral profile of the patient (note the maintenance of the profile). (b) Final extraoral frontal view of the patient. (c) Final extraoral view of smile of the patient (please note improved smile).



**FIGURE 13.** (a) Final intraoral frontal view of the patient. (b) Final intraoral right view of the patient. (c) Final intraoral left view of the patient. (d) Final intraoral upper occlusal view of the patient.

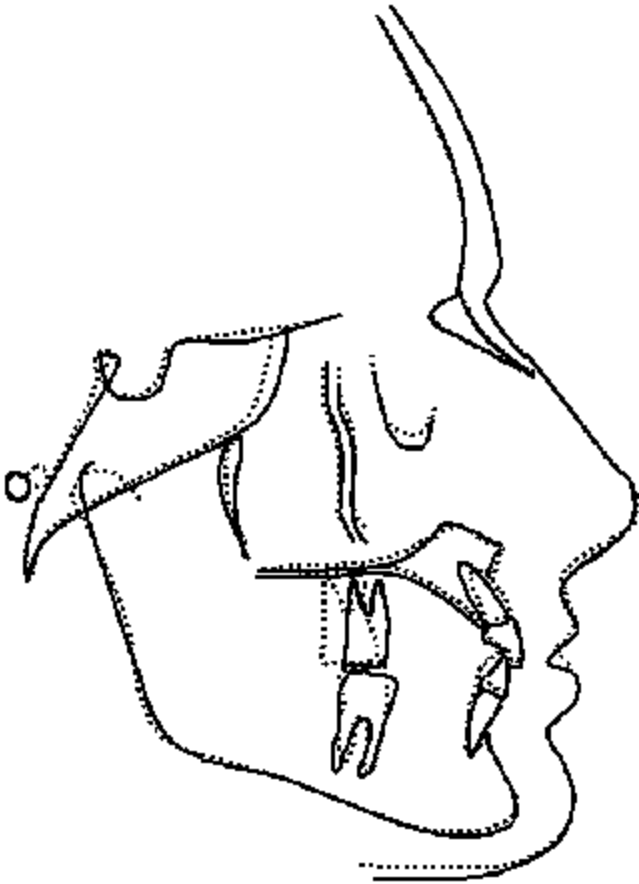
The purpose of placing the implant at this inclination was to have adequate bone volume around the implant. The tracing of the maxilla was enabled by this procedure, and the risk of surgical penetration into the nasal cavity also was avoided.

In this study, the use of surgical templates reduced operation time, increased the precision of implant angulation, eliminated improper positioning of the implant, avoided damage to anatomical structures, thereby confirming the results of other authors who have described the use of surgical templates.<sup>40,41</sup> Schlegel et al<sup>42</sup> studied the anatomical basis for the placement of the palatal implant by obtaining trephine bur biopsy samples from the palate for histological observations. Their results showed that the anterior region of the median suture palatine is often less ossified than the posterior region. Their findings support our method of using the paramedian regions for the place-

ment of the implant to avoid the connective tissues of the palatine suture.

### CONCLUSIONS

A palatal implant was used for effective maintenance of anchorage and in space-gaining procedures in a patient. The molars translated distally without the loss of anchorage and tipping. No cooperation was required (no headgear), except good oral hygiene. Minimal invasive techniques eased the surgical procedure and reduced the operation time. The paramedian region could be a suitable implant site for orthodontic purposes. Transmucosal placement eliminates second-stage surgery. Use of a three-dimensional surgical template eliminated faulty implant placement and simplified intraoperative decisions concerning correct inclination of the long axis of the implant. Further work needs to be done with an increased number of treated cases.



**FIGURE 14.** Cephalometric superimposition of the patient. Solid line = Initial, Dotted line = Final.

## ACKNOWLEDGMENTS

We thank Drs Tosun Tosun and Hussam Shaban.

## REFERENCES

1. Egolf RJ, Begole EA, Upshaw HS. Factors associated with orthodontic patient compliance with intraoral elastic and headgear wear. *Am J Orthod.* 1990;97:336–348.
2. American Association of Orthodontists. Special bulletin on extraoral appliance care. *Am J Orthod Dentofacial Orthop.* 1975;75:457.
3. American Association of Orthodontists Bulletin. Preliminary results of head gear survey. *The Bulletin.* 1982;1:2.
4. Bondemark L, Kuroi J. Distalization of first and second molars simultaneously with repelling magnets. *Eur J Orthodont.* 1992;14:264–272.
5. Erverdi N, Koyuturk Ö, Kucukkeles N. Nickel-titanium coil springs and repelling magnets: a comparison of two different intra-oral molar distalization techniques. *Br J Orthodont.* 1997;24:47–53.
6. Fuhrmann R, Wehrbein H, Diedrich P. Anteriore Verankerungsqualität der odifizierten Nance Apparatur bei der Molarendistalisierung. *Kieferorthop.* 1994;8:45–52.
7. Keles A, Sayinsu K. A new approach in maxillary molar distalization: intraoral bodily molar distalizer. *Am J Orthod Dentofacial Orthop.* 2000;117:39–48.
8. Ödman J, Lekholm U, Jemt T, Branemark P-I, Thilander B. Osseointegrated titanium implants—a new approach in orthodontic treatment. *Eur J Orthodont.* 1988;10:98–105.
9. Roberts WE, Smith R, Zilberman Y, Mozsary PG, Smith RS. Osseous adaptation to continuous loading of rigid endosseous implants. *Am J Orthod.* 1984;86:95–111.
10. Roberts WE, Helm FR, Marshall KJ, Gonglof RK. Rigid endosseous implants for orthodontic and orthopedic anchorage. *Angle Orthod.* 1989;59:247–256.
11. Roberts WE, Marshall KJ, Mozsary PG. Rigid endosseous implant utilized as anchorage to protract molars and close an atrophic extraction site. *Angle Orthod.* 1990;60:135–152.
12. Turley PK, Kean C, Sehur J, Stefanac J, Gray J, Hennes J, Poon LC. Orthodontic force application to titanium endosseous implants. *Angle Orthod.* 1988;58:151–162.
13. Van Roekel NB. The use of Branemark system implants for orthodontic anchorage: report of a case. *Int J Oral Maxillofac Implants.* 1989;4:341–344.
14. Chen J, Chen K, Garetto LP, Roberts WE. Mechanical response to functional and therapeutic loading of a retromolar endosseous implant used for orthodontic anchorage to mesially translate mandibular molars. *Implant Dent.* 1995;4:246–258.
15. Melsen B, Lang NP. Biological reactions of alveolar bone to orthodontic loading of oral implants. *Clin Oral Impl Res.* 2001;12:144–152.
16. Linder-Aronson S, Nordenram A, Anneroth G. Titanium implant anchorage in orthodontic treatment an experimental investigation in monkeys. *Eur J Orthod.* 1990;12:414–419.
17. Ödman J, Grondahl K, Lekholm U, Thilander B. The effect of osseointegrated implants on the dento-alveolar development. A clinical and radiographic study in growing pigs. *Eur J Orthod.* 1991;13:279–286.
18. Sennerby L, Ödman J, Lekholm U, Thilander B. Tissue reactions towards titanium implants inserted in growing jaws. A histological study in the pig. *Clin Oral Impl Res.* 1993;4:65–75.
19. Smalley WM, Shapiro PA, Hohl TH, Kokich VG, Branemark P-I. Osseointegrated titanium implants for maxillofacial protraction in monkeys. *Am J Orthod Dentofacial Orthop.* 1988;94:285–295.
20. Thilander B, Ödman J, Grondahl K, Lekholm U. Aspects on osseointegrated implants inserted in growing jaws. A biometric and radiographic study in the young pig. *Eur J Orthod.* 1992;14:99–109.
21. Haanaes HR, Stenvik A, Beyer Olsen ES, Tryti T, Faehn O. The efficacy of two-stage titanium implants as orthodontic anchorage in the preprosthodontic correction of third molars in adults: a report of three cases. *Eur J Orthod.* 1991;13:287–292.
22. Ödman J, Lekholm U, Jemt T, Thilander B. Osseointegrated implants as orthodontic anchorage in the treatment of partially edentulous adult patients. *Eur J Orthod.* 1994;16:187–201.
23. Thilander B, Ödman J, Grondahl K, Friberg B. Osseointegrated implants in adolescents. An alternative in replacing missing teeth? *Eur J Orthod.* 1994;16:84–95.
24. Higuchi KW, Slack JM. The use of titanium fixtures for intraoral anchorage to facilitate orthodontic tooth movement. *Int J Oral Maxillofac Implants.* 1991;6:338–344.
25. Abels N, Schiel HJ, Hery-Langer G, Neugebauer J, Engel M. Bone condensing in the placement of endosteal palatal implants: a case report. *Int J Oral Maxillofac Implants.* 1999;14:849–852.
26. Glatzmaier J, Wehrbein H, Diedrich P. Die Entwicklung eines resorbierbaren Implantatsystems zur orthodontischen Verankerung. *Fortschr Kieferorthop.* 1995;56:175–181.
27. Triaca A, Antonini M, Wintermantel E. Ein neues Titan-Flaschschraubenimplantat zur Verankerung am anterioren Gaumen. *Inf Orthod Orthop.* 1992;24:251–257.
28. Turley PK, Shapiro PA, Moffett BC. The loading of bioglass-

- coated aluminum oxide implants to produce sutural expansion of the maxillary complex in the pigtail monkey (*Macaca nemestrina*). *Arch Oral Biol.* 1980;25:459–469.
29. Wehrbein H. Enossale Titanimplantate als orthodontische Verankerungselemente. Experimentelle Untersuchungen und klinische Anwendung. *Fortschr Kieferorthop.* 1994;5:236–250.
  30. Wehrbein H, Glatzmaier J, Mundwiller U, Diedrich P. The ortho-system: a new implant system for orthodontic anchorage in the palate. *J Orofac Orthop.* 1996;57:142–153.
  31. Ohmae M, Saito S, Morohashi T, et al. A clinical and histological evaluation of titanium mini-implants as anchors for orthodontic intrusion in the beagle dog. *Am J Orthod Dentofacial Orthop.* 2001;119:489–497.
  32. Umemori M, Sugawara J, Mitani H, Nagasaka H, Kawamura H. Skeletal anchorage system for openbite correction. *Am J Orthod Dentofacial Orthop.* 1999;115:166–174.
  33. Erverdi N, Tosun T, Keles A. A new anchorage site for the treatment of anterior open bite: Zygomatic anchorage. A case report. *World J Ortho.* 2002;3:147–153.
  34. Tosun T, Keles A, Erverdi N. Method for the placement of palatal implants. *Int J Oral Maxillofac Implants.* 2002;17:95–100.
  35. Mombelli A, van Oosten MAC, Schürch E, Lang NP. The micro-biota associated with successful or failing osseointegrated titanium implants. *Oral Microbiol Immunol.* 1987;2:145–151.
  36. Bernhart T, Vollgruber A, Gahleitner A, Dörtbudak O, Haas R. Alternative to median region of the palate for placement of an orthodontic implant. *Clin Oral Impl Res.* 2000;11:595–601.
  37. Keles A. Maxillary unilateral molar distalization with sliding mechanics: a preliminary investigation. *Eur J Orthod.* 2001;23:507–515.
  38. Keles A, Pamukcu B, Tokmak EC. Bilateral molar distalization with sliding mechanics: Keles Slider. *World J Orthod.* 2002;3:57–66.
  39. Keles A. Unilateral distalization of a maxillary molar with sliding mechanics: a case report. *J. Orthod.* 2002;29:97–100.
  40. Cehreli MC, Sahin S. Fabrication of a dual-purpose surgical template for correct labiopalatal positioning of dental implants. *Int J Oral Maxillofac Implants.* 2000;15:278–282.
  41. Higginbottom FL, Wilson TG. Three-dimensional templates for placement of root-form dental implants: a technical note. *Int J Oral Maxillofac Implants.* 1996;11:787–793.
  42. Schlegel KA, Kinner F, Schlegel KD. The anatomic basis for palatal implants in orthodontics. *Int J Adult Orthod Orthognath Surg.* 2002;17:133–139.